

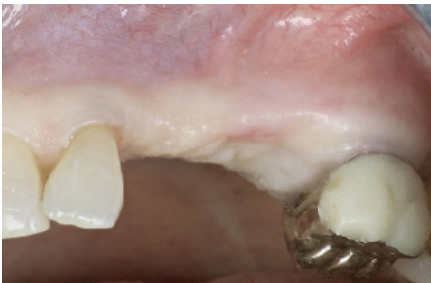
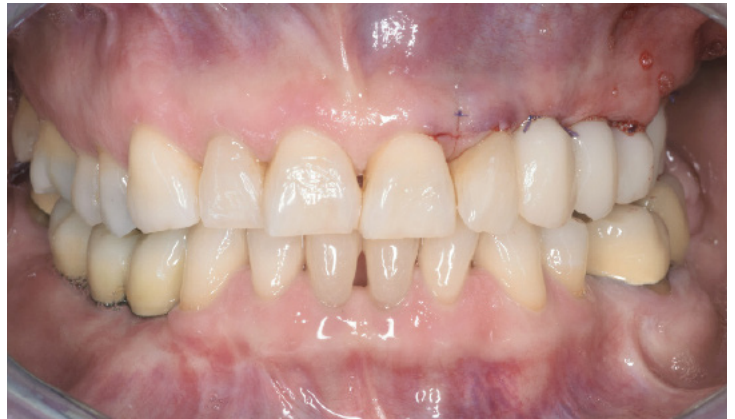
Marco Toia, DDS, PhD.  
Private Practice, Italy

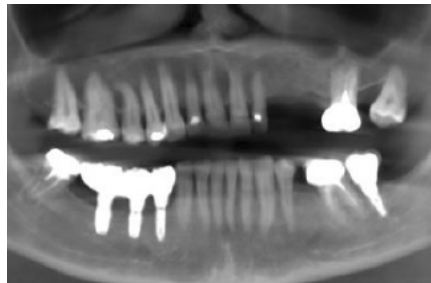**Immediate loading in partially edentulous maxilla with PrimeTaper EV implants and Uni Abutment EV**

A 68-year-old female patient, ASA-1 presented partial edentulism of the left canine and the two premolars, was wearing a partial removable denture anchored on the left molar. The patient was experiencing pain on the molar tooth and requested an immediate fixed restoration to replace the partial removable denture.

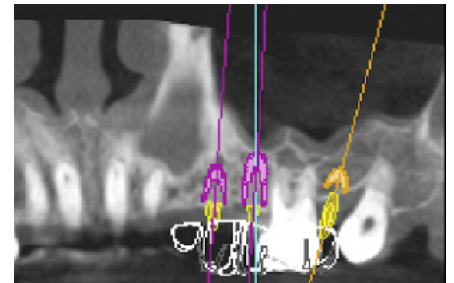
The PrimeTaper EV implants were inserted according to digital planning and the abutments were immediately positioned. A digital impression was taken and after 2 hours a temporary screw-retained implant-supported restoration was delivered to the patient.



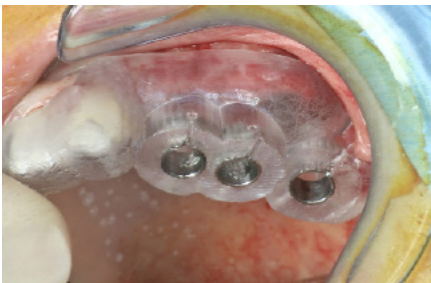1. Pre-operative situation showing the partially edentulous maxilla.



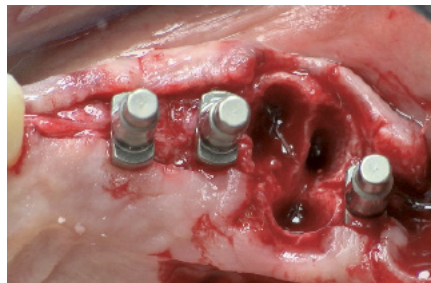2. Pre-operative radiograph.



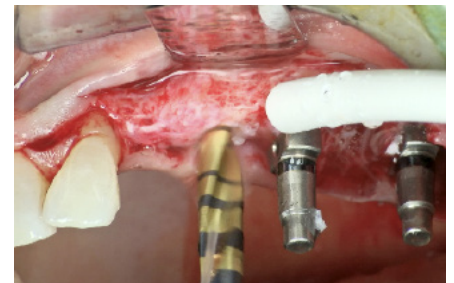
3. Digital implant treatment planning was performed in Simplant software for three implants in the maxilla, and a surgical guide was produced.




4. After making the incision, the surgical guide was used for the first drill to ensure correct implant position.



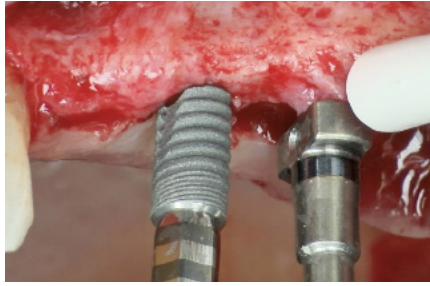
5. Direction indicators in position to evaluate the implant position.



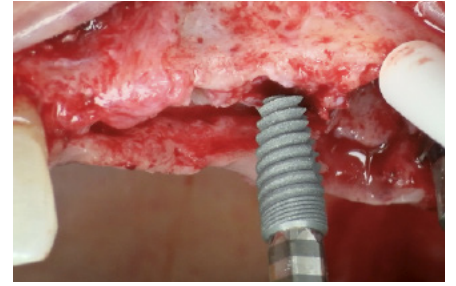
6. The recommended drilling protocol for PrimeTaper EV was followed for placement in position 12 (FDI 24). The drilling procedure ended with drill #3. Drill #4 was used for 2mm cortical preparation.



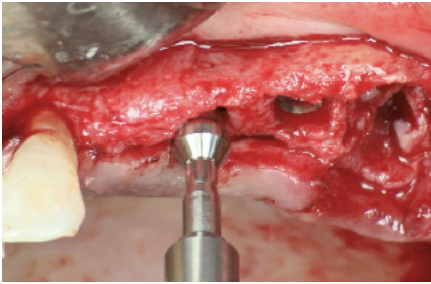
**7.** The new design of Implant Driver EV features a PEEK portion on the tip, which is activated when installed into the implant to secure the engagement.



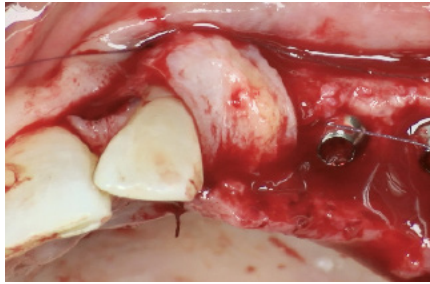
**8.** PrimeTaper EV Ø3.6 11mm implant installation in position 12 (FDA 24). The tapered design allowed for an easy insertion of the implant before the stated rotational movement.



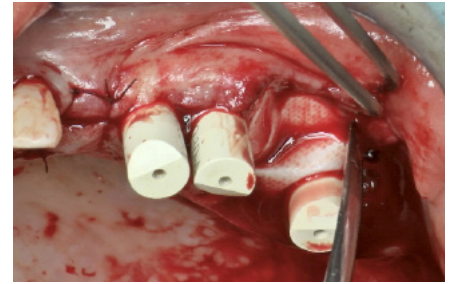
**9.** PrimeTaper EV Ø3.6 9mm implant installation in position 13 (FDA 25).



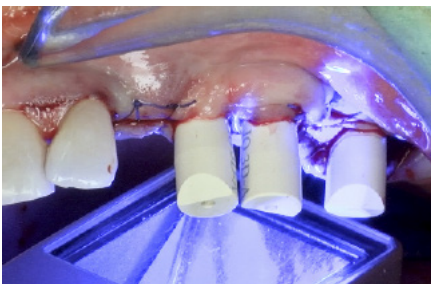
**10.** Index free one-piece Uni Abutment EV (2.0 mm height) were installed and tightened to the recommended torque (25 Ncm).



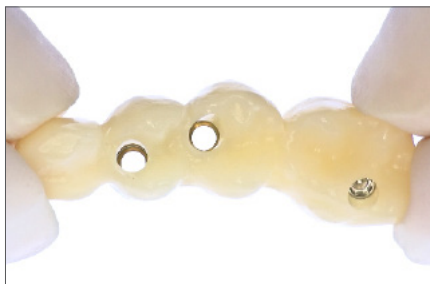**11.** OSSIX Bone inserted in the post-extraction site in position 14 (FDI 26) and connective tissue graft in position 11 (FDI 23).



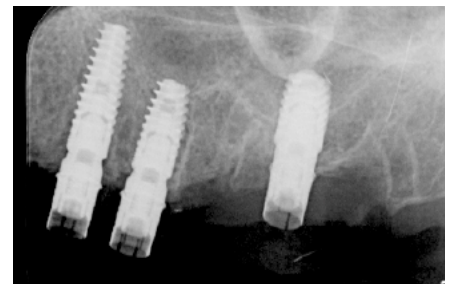
**12.** OSSIX Plus was used to cover the OSSIX Bone in position 14 (FDI 26).



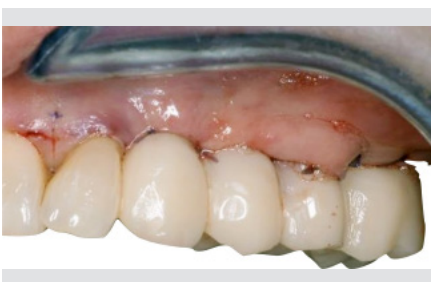**13.** Scan bodies were attached for digital impression taking.



**14.** Temporary screw-retained restoration for Immediate Smile.



**15.** Radiographic evaluation.



**16.** Temporary screw-retained restoration in place.

This case report is published as an inspiration for you as a clinician / technician and not necessarily as a recommendation from Dentsply Sirona.