

## Immediate reconstruction of an edentulous upper jaw with PrimeTaper EV

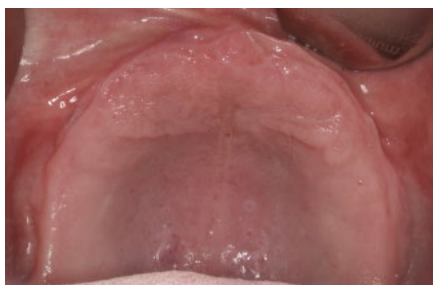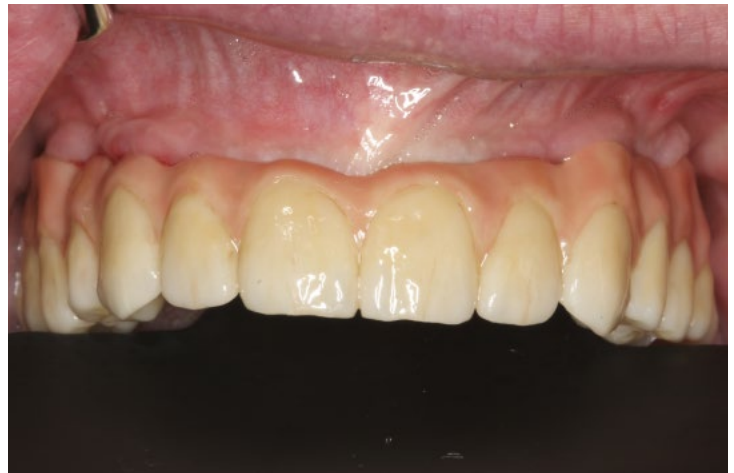A 55-year-old male patient complained about the retention of his upper full denture, and requested a fixed solution. The Dual Scan protocol was used to visualize bone, soft tissue thickness and denture position in the Simplant Software. Four PrimeTaper EV Ø3.6 implants were planned according to the position of his denture and four MultiBase abutments were visualized accordingly. Prior to surgery intraoral scans of edentulous upper and the dentate lower jaw were performed. The denture was used first as a surgical guide and then as a provisional bridge, after removing the palate. Immediately after implant placement the abutment position was registered with an intraoral scan and a final Atlantis BridgeBase with a full zirconia bridge was placed eight weeks after implant installation.



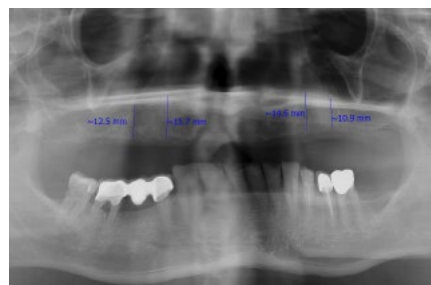**Dr. Mischa Krebs**  
Private Practice  
Dr. Krebs & Colleagues,  
Alzey, Germany



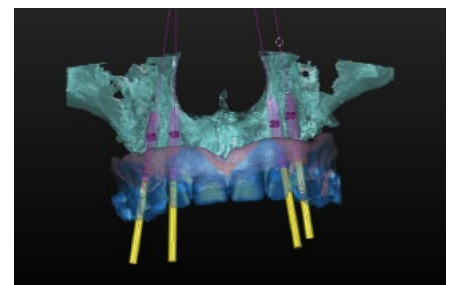
**ZTM Alexander Müller**  
Dental Lab Müller &  
Edelhoff, Wörrstadt,  
Germany



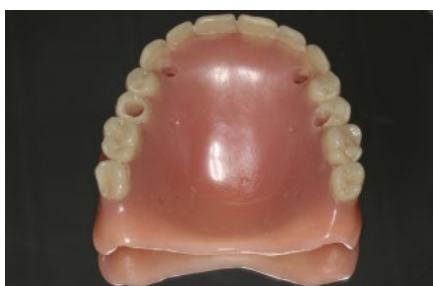**1.** Pre-operative situation showing the edentulous upper jaw. The patient requested a fixed solution.



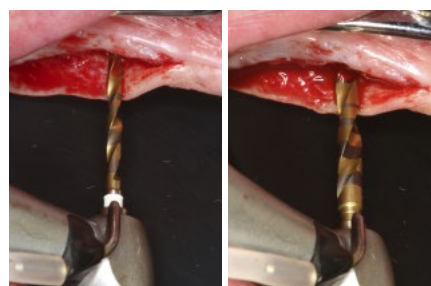
**2.** Pre-operative radiograph.



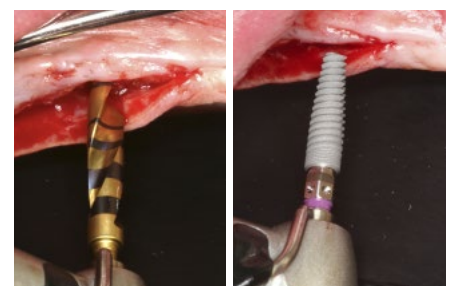
**3.** Implant treatment planning in Simplant software using the Dual Scan protocol to visualize tooth position, as well as abutment position. Four PrimeTaper EV Ø3.6 implants were planned for immediate restoration.



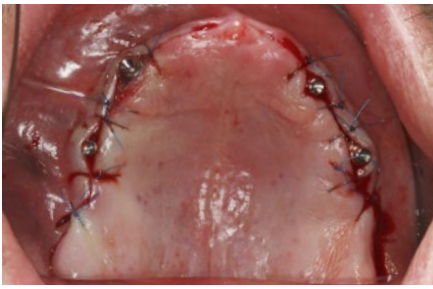
**4.** The existing denture is adapted to be used as surgical guide and provisional bridge for immediate loading.



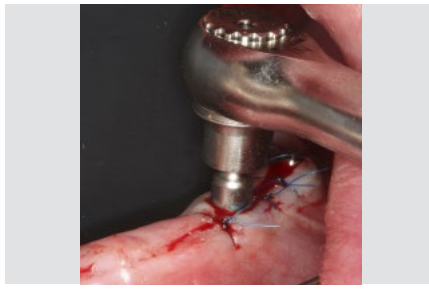**5.** Implant bed preparation following the recommended drilling protocol for the planned PrimeTaper EV Ø3.6 implant (drills #1 and 3).



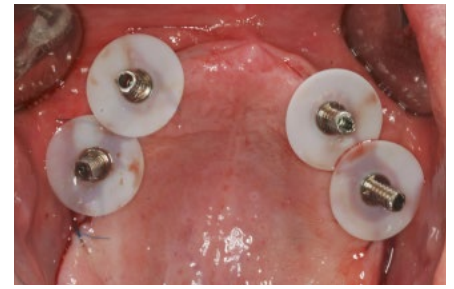
**6.** Coronal perforation of the cortical layer with drill #4 and implant insertion.



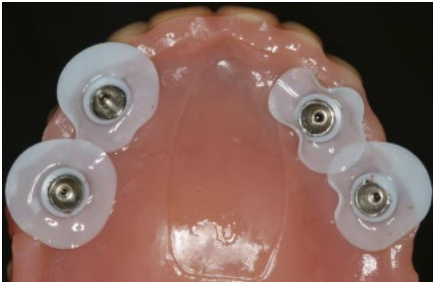7. Multibase Abutments inserted for immediate loading.



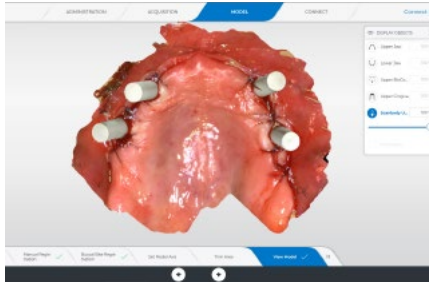
8. The abutments were torqued to 25 Ncm.



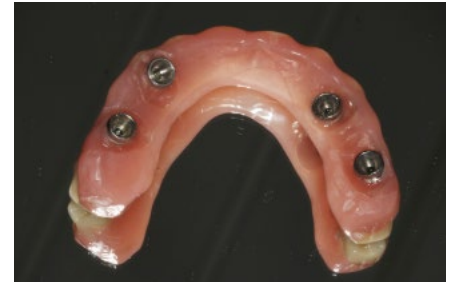9. Temporary cylinders prepared with SynCone Silicone Sleeve for intraoral gluing.



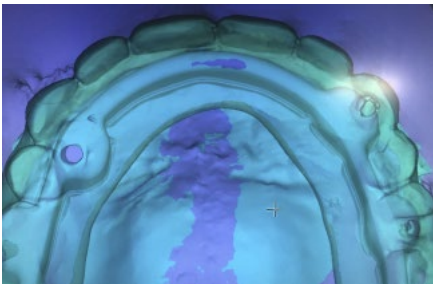
10. Intraoral gluing of the temporary cylinders into the existing denture.



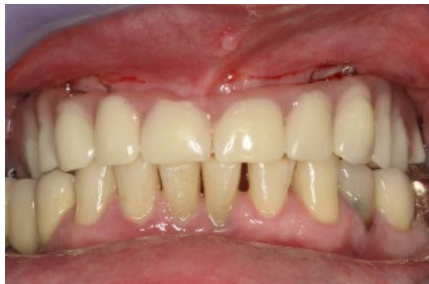11. Intraoral scan of the abutment position, antagonists, provisional reconstruction and jaw relation for the manufacturing of the final reconstruction.



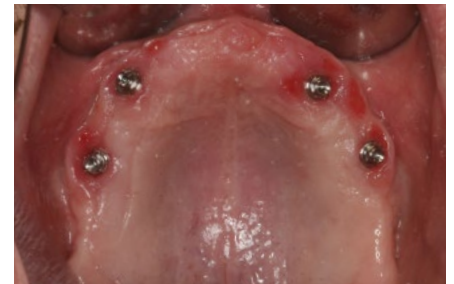12. Seating of the provisional bridge.



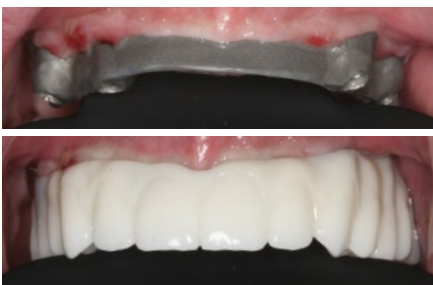13. Design of the final Atlantis Bridge.



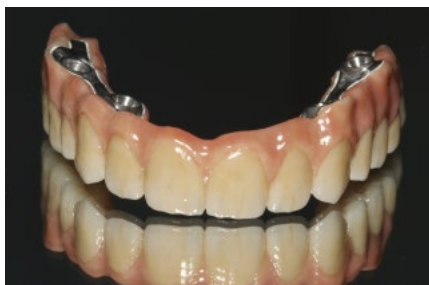14. Temporary restoration in place.



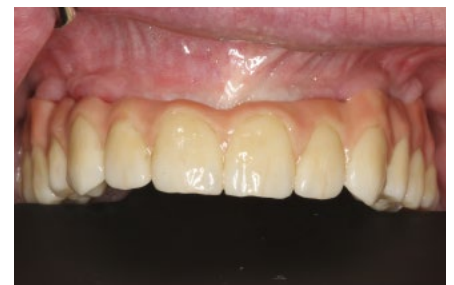15. Healed soft tissue eight weeks after implant installation.



16. Try-in of the Atlantis BridgeBase with a printed wax up which will be copy milled in zirconia.



17. Final Atlantis BridgeBase with full zirconia bridge.



18. Final bridge seated eight weeks after implant installation.

This case report is published as an inspiration for you as a clinician / technician and not necessarily as a recommendation from Dentsply Sirona.