

TruNatomy®

CLINICAL CASES AND TESTIMONIALS

Collection of Cases

NOVEMBER 2022





TruNatomy® Table of cases

	Page
About TruNatomy	4
Acute apical periodontal abscess	6
Conservative shaping following a trauma	8
Symptomatic apical peridodontitis	10
Complexity with long and calcified roots	12
Shaping long curved and thin roots	14
Conservative management of a premolar	16
Coronal fractures in lower anterior teeth	18
A restorative approach to Endodontics	20
A conservative approach for a premolar with three thin roots	22
A case of root canal obliteration	24
A complex maxillary first premolar with a double curvature	26

TruNatomy®

TruNatomy® is a comprehensive endodontic solution that offers:

- Smooth feeling during preparation
- Improved performance and efficacy¹
- More space for debridement and debris removal¹
- Respect of the natural tooth anatomy
- Preservation of tooth structure

TruNatomy® combines Swiss precision with advanced engineering to offer the benefits of improved performance with increased respect of the tooth anatomy.¹

TruNatomy® has been developed with skilled practitioners, Dr. George Bruder and Dr. Ove Peters, leaders in the field of endodontics.



Prof. Ove Peters
School of Dentistry,
University of
Queensland Brisbane,
Australia



Dr. George Bruder
International
Dental Institute
Palm Beach Gardens and
Fort Lauderdale, Florida

A white handwritten signature of Prof. Ove Peters.

A white handwritten signature of Dr. George Bruder.

In this collection of testimonials, clinicians are sharing their experiences with TruNatomy®. From simple cases² to complex ones³, TruNatomy® is a solution that follows clinicians in their daily practice.

A design adapted to difficult anatomies

They found that TruNatomy® was particularly well adapted to thin, curved and calcified canals^{3,4,5} thanks to the increased flexibility, smaller MFD and design of the instruments.

Conservative and efficient

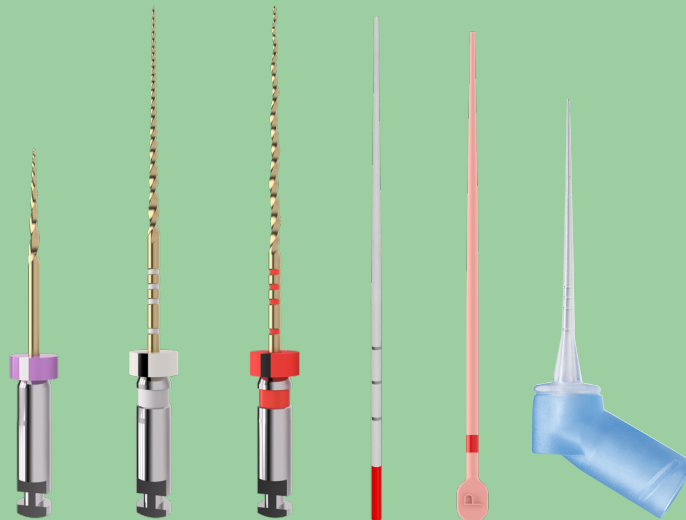
Their experiences highlight that the strength of the instrument lies in its ability to keep the tooth strength and integrity^{4,3,6} while still allowing deep cleaning.^{2,3,6}

Smooth feeling and ease of use

The preparation is smooth and gives a feeling of satisfaction to clinicians.^{5,6}

A restorative pathway

They have been able to focus on dental structure preservation (e.g. peri-cervical dentin preservation) during both the endodontic and restorative steps to increase tooth longevity.³



¹ Compared to ProTaper Next®
² Dr. Filippo Santarcangelo (S. 8)
³ Dr. Jonathan Cowie (S. 12)
⁴ Dr. Pradyumna D Joshi (S. 6)
⁵ Dr. Mauro Amato (S. 14)
⁶ Dr. Krishna Vays (S. 16)



About Dr. Joshi

Dr. P. D. Joshi graduated from Nair Hospital Dental College, Mumbai: BDS in 1980, MDS (Conservative Dentistry) in 1983. He is an eminent consultant endodontist practicing in Mumbai since 1980.

He offers his services as Head of the Dept of Dentistry and Hon. Consultant endodontist at Lilavati Hospital & Medical Research Centre. He is on the panel of Bhabha Atomic Research Centre as consultant endodontist.

Dr. Joshi runs his own private practice mainly focusing on micro-endodontics, implants & restorative dentistry for which he has taken training at various centers across world including University of Pennsylvania.

He runs his own endodontic training centre in Mumbai. He has taught at the University of Kebangsaan at Kuala Lumpur, Malaysia. He is an international speaker & lecturer in South Asia. He has published original research articles, and writes in many national and international journals.

Acute apical periodontal abscess with narrow roots and calcified pulp chamber

About the patient

Male, aged 61

Tooth: 46 lower right mandibular first molar

Chief complaint

Acute pain when biting and chewing

Notable dental history

Patient with hypertension but under control. Previously treated (endo, extraction). Periodontal condition: average.

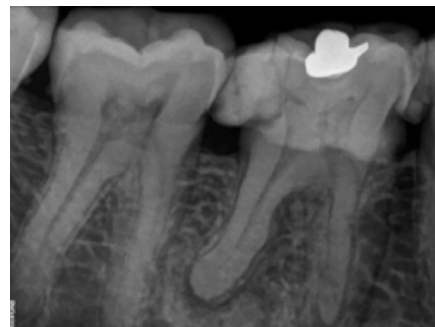Diagnostic findings

Cold test: negative

Percussion: 8/10

Diagnosis

Preoperative radiograph indicates a periapical lesion and a carious tooth. The roots were very narrow, the canal walls thickness were diminished and I feared that a greater taper instrument would weaken even more the tooth.



Preoperative radiographs

“I did not want to compromise the tooth strength and integrity”

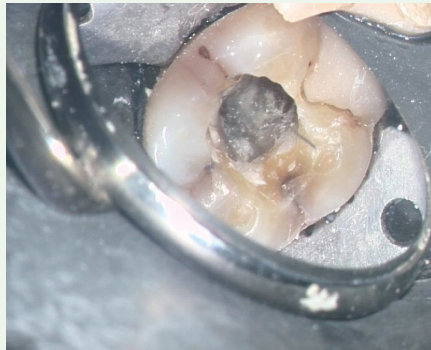Treatment plan

Access opening performed with a round bur and modified with the EndoZ bur. Calcifications were removed thanks to an ultrasonic tip (Start-X™ #3).

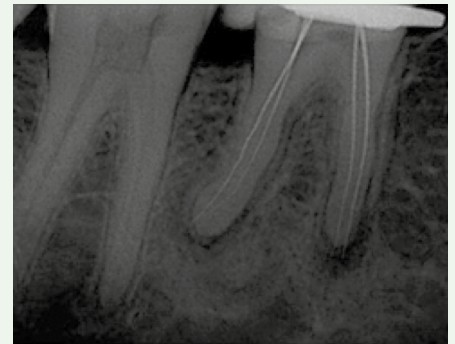
The TruNatomy® Orifice Modifier was used to modify the 1/3rd of the canals and the initial scouting was done with a K-file #10; followed by TruNatomy® glider, small and prime. The canals were obturated with appropriate GP cones and warm vertical compaction technique once disinfected.

Patient was given a temporary cement dressing prior to definitive restoration.

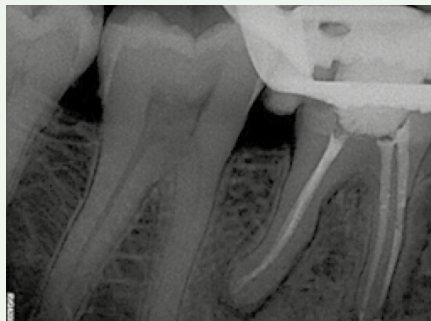
Core build up was carried out with a combination of SDR® and bulkfill. Patient was given a PFM crown in the following appointment.



Access cavity after the removal of the calcifications



WL radiograph



Postoperative radiographs



About Dr. Santarcangelo

Dr. Santarcangelo graduated from the University of Bari School of Medicine and Surgery in 1996.

He was trained in Endodontics by Dr. Arnaldo Castellucci' Postgraduate course in Florence.

He is an active member of the Italian Endodontic Society.

Speaker at numerous conferences and congresses in Italy and abroad.

Speaker at the AAE (American Association of Endodontists) in the San Diego 2010 and San Antonio 2011 editions, invited speaker in the Hawaii edition 2013.

Invited Lecturer at the Harvard University, Boston (USA).

Adjunct professor in Endodontics at the degree course in dentistry and dental prosthetics at the University of Padua.

Professor at the Two years Postgraduate course in Madrid (Spain), University Rey Juan Carlos.

He maintains a clinical practice limited to endodontics in Bari, Italy.

Conservative shaping following a trauma

About the patient

Male, aged 55
Tooth: upper canine

Chief complaint

None

Notable dental history

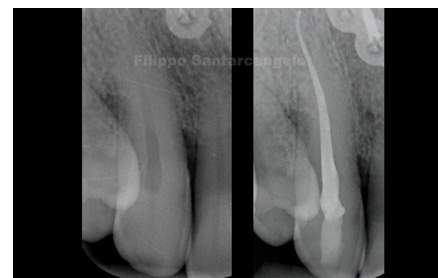The tooth did not have caries but had become necrotic after a car accident. A metallic structure had been placed to stabilize the bone after a fracture.

Diagnostic findings

Cold test: negative

Diagnosis

Despite the X-ray appearance, the tooth is fragile. It lost its vitality after the trauma and this is synonymous of damage.



Pre and Post X-Rays
The Root canal anatomy has been perfectly respected and filled with warm vertical compaction with GuttaSmart.

“A simple but very significant case.”

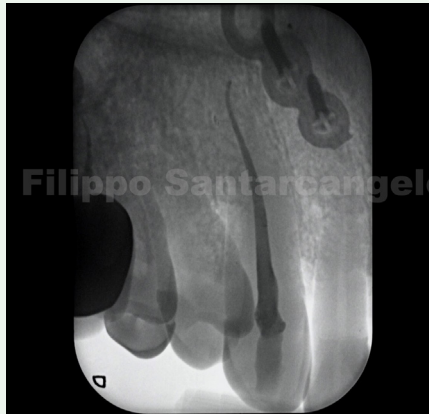Treatment plan

The objective is to limit as much as possible extra damages: A conservative shape is therefore needed .

The coronal third of the tooth is large by nature. Thanks to its slim design, the instrument did not enlarge unnecessary the coronal third.

The post operative X-ray shows that in the coronal third there was no shaping.

On top of being conservative, TruNatomy® allows deep cleaning following the dedicated irrigation protocol.



The smooth curvatures of this canine were beautifully shaped by TruNatomy®, ensuring high respect of the original anatomy

“TruNatomy® is conservative and still allows deep cleaning”



About Dr. Ikram

Dr. Omar Ikram is a Specialist Endodontist and director of Specialist Endo Crows Nest in Sydney. He works as a senior Specialist at Sydney Dental Hospital.

In 1997 he completed his BDS at Otago University. His interest in Endodontics lead him to studying a Masters of Clinical Dentistry in Endodontology, at Kings College, UK and during this he gained the Membership of Restorative Dentistry, from the Royal College of Surgeons Edinburgh.

For his work in the wider dental community, he was inducted into the International College of Dentists in 2019.

Symptomatic apical peridodontitis associated with irreversible pulpitis

About the patient

Male, aged 28
Tooth: upper first molar 26

Chief complaint

Sensitivity to cold liquids on the upper left side of his mouth

Notable dental history

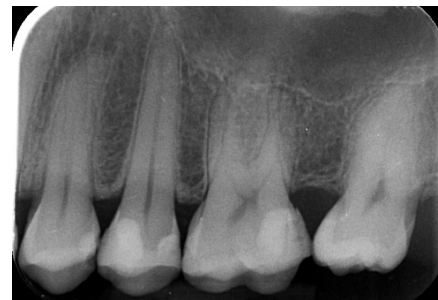Caries associated with tooth 25. The tooth had been restored by the general dental practitioner, yet the sensitivity remained. A restoration in tooth 26 had been placed a long time ago.

Diagnostic findings

Cold test: positive
Percussion test: positive

Diagnosis

Symptomatic apical periodontitis associated with an irreversible pulpitis.



Preoperative radiograph showing deep restorations in teeth 25 and 26

Treatment plan

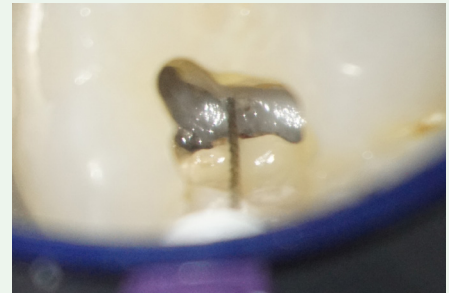
Root canal treatment of tooth 26, followed by restoration of the access with a core material. The patient was advised to have a full crown fitted by his general dental practitioner to prevent fracture, once tooth 26 had become asymptomatic, following root canal treatment.

The TruNatomy® Prime (26/04v) was used to complete preparation of the mesiobuccal1 mesiobuccal2 and distobuccal canals.

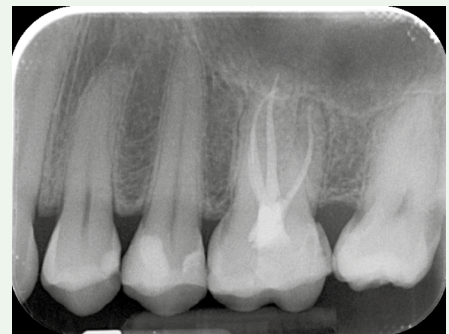Due to the straight and wide anatomy of the palatal canal a ProTaper Next® X3 (30/07) was used to complete preparation. Irrigation was carried out using 6% sodium hypochlorite and 15% EDTA with the TruNatomy® Irrigation Needle.

Activation of sodium hypochlorite, using the EndoActivator® was performed. Calcium hydroxide was placed in the canals and the access cavity closed with a base of Cavit in the pulp chamber and a glass ionomer temporary restoration.

4 weeks later, as the resolution of symptoms had occurred, it was decided that the canals could be filled and the core restoration placed. Phosphoric acid 37% was used to etch the dentin and Prime&Bond active® was applied to the etched dentin and cured, using the SmartLite® Pro. SDR® flow was used as a base over the gutta-percha and this was light cured. Composite was then placed in the access cavity, over the cured SDR® flow and light cured.



Location of all 4 canals in tooth 26 was possible with minimal loss of peri-cervical dentine



Postoperative radiograph showing satisfactory filling of the canals and restoration



About Dr. Cowie

Jonathan Cowie is a Specialist Endodontist working in private practice in Bath, UK.

He has worked in endodontic referral practice for the last decade and completed both a Diploma in Endodontics at The Royal London Hospital and subsequently Specialist Endodontics Training at Kings College, London.

Alongside his clinical work, Jon is a very active educator. He runs many hands-on courses through his joint education venture, Contemporary Endodontics and teaches as a clinical demonstrator on the MSc in Endodontics at Kings College, London. The hands-on courses always focus on restoratively driven endodontics and the key philosophy of dentine preservation.

Jon and his colleague Luca Moranzoni were one of the first clinicians to put together training for dentists showcasing the end-to-end endodontic-restorative workflow in these intensive short courses.

A complex case with long roots and a calcified system

About the patient

Male, aged 48
Tooth: Lower molar (LL6)

Chief complaint

Discomfort on biting from the lower left first molar (after having an acute flare-up with swelling).

Notable dental history

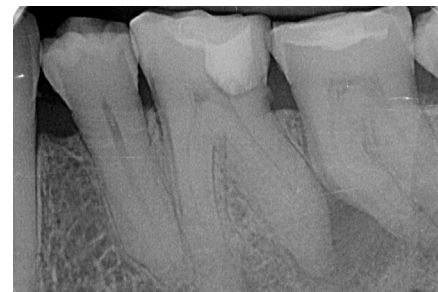None

Diagnostic findings

Tenderness on palpation and on percussion but no mobility.

Diagnosis

Periapical radiolucency associated primarily with the distal root and loss of lamina dura on the mesial root.



Preoperative radiograph

“TruNatomy® respects the anatomy without compromising the ability to irrigate.”

Treatment plan

Access cavity approach with a leveraged access utilising the distal restoration to gain access preserving mesial pericervical dentin.

Instrumentation with TruNatomy® files in a conventional approach.

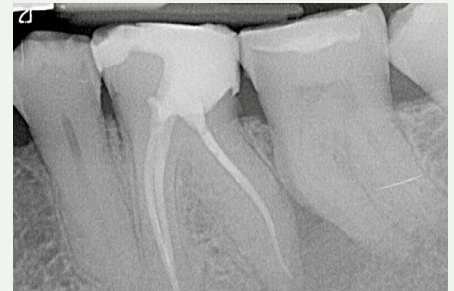
Irrigation with 5.25% Sodium Hypochlorite throughout the procedure with the TruNatomy® Irrigation Needle

Obturation with TruNatomy® Prime GP and AH Plus®. Warm vertical compaction technique.

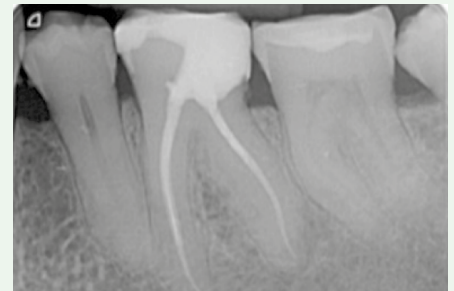Direct restoration using Palodent® Plus Matrices, SDR® and Ceram.x Spectra™ ST.

TruNatomy® was chosen in this case to allow a caries leveraged approach and a focus on pericervical dentin preservation especially on the mesial aspect where the tooth had a more minimal restoration.

The 14 months review confirmed the success of treatment. Final restoration with a ceramic onlay with margin elevation to again minimize the impact of dentin preparation that would reduce the thickness of dentin at the base of the cusp.



Postoperative radiograph



14 month follow up showing resolution of the periapical radiolucency



About Dr. Amato

Dr. Mauro Amato graduated in dentistry from the University of Basel in Switzerland. He works as a senior physician at the Department of Conservative dentistry with a focus on endodontology and is involved in teaching and research in addition to patient treatment.

He is a lecturer at various Endo Curricula in Germany and gives advanced training courses with a focus on endodontology.

He has been a board member of the Swiss Society of Endodontology (SSE) since 2014.

2005-2011 Assistant and research assistant with focus on Endodontics at the Clinic for Periodontology, Endodontology and Cariology, University of Basel (Prof. Dr. R. Weiger).

2011 Dissertation on root canal irrigation.

Since 2015, he has been a member of the Basel Dental Trauma Centre.

Today he works in his private clinic in Basel, Switzerland.

Shaping long curved and thin roots

About the patient

Female, aged 46
Tooth: Lower first molar

Chief complaint

Constant pain

Notable dental history

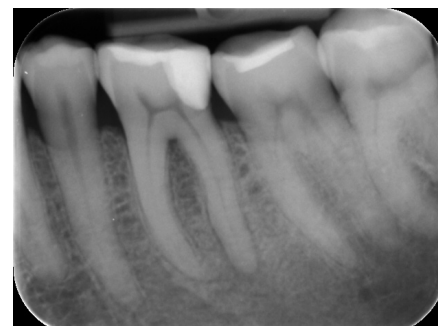Deep filling a few years before

Diagnostic findings

Cold test: overreacting positive
Percussion test results: positive
Palpation test results: negative

Diagnosis

Acute pulpitis



Preoperative radiographs

***“TruNatomy® is a conservative and flexible root canal shaping system:
a larger tapered instrument would have weakened the tooth.”***

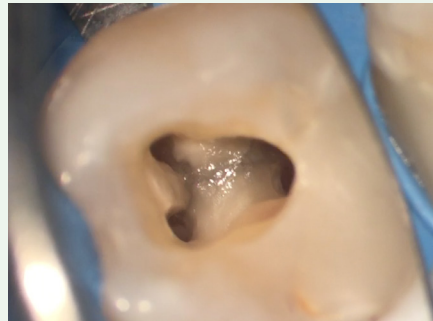
Treatment plan

Conservative access cavity followed by the TruNatomy® sequence (Orifice Modifier, Glider and Prime).

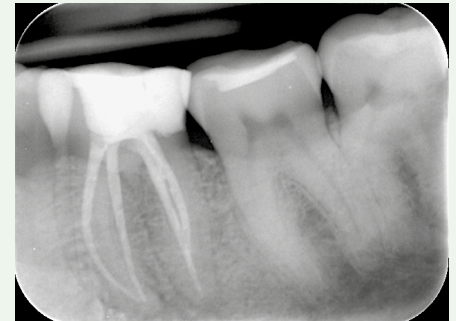
Irrigation with TruNatomy® Irrigation Needle and ultrasonic irrigation.

Obturation using single cone without a post.

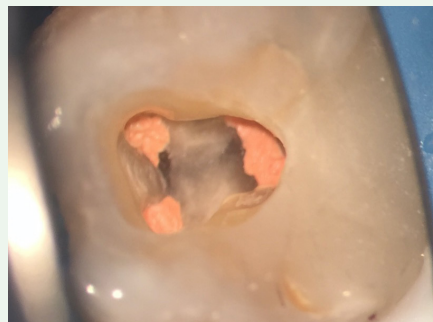Restoration using an adhesive filling.



Root canals with a conservative access cavity



Postoperative radiograph



Root canals filled

***“The preparation is smooth and I like the way
the instrument works in the root canal.”***



About Dr. Vyas

Dr. Krishna Vyas is a distinguished Endodontist & Smile designer from Central India. She got her bachelor of Dental Surgery from prestigious SDM Dental College in India and practiced general dentistry for 5 yrs.

Thereafter, she went on to do masters in Endodontics and restorative dentistry and attained her MDS degree in 2011 bagging a Gold medal.

Since then she does specialty practice focusing on Micro Endodontics and Smile enhancement.

She is Director of Vyas Dental Inn and Raipur Multispeciality Dental Clinic, Research centre and Endodontic training centre with in-house CBCT facility.

She is also involved in teaching as an associate professor at Maitri Dental College, Durg, India. She empowers fellow colleagues with her Youtube channel where she posts educational videos. To her credit, she has won several awards including “Highly Commended Outstanding Dentist of the Year” Famdent Award in 2017.

Conservative management of a premolar with Irreversible Pulpitis with narrow roots and multiplanar curves in bucco lingual direction

About the patient

Female, aged 41
Tooth: Maxillary left 2nd premolar.

Chief complaint

Pain in left upper back region of jaw

Notable dental history

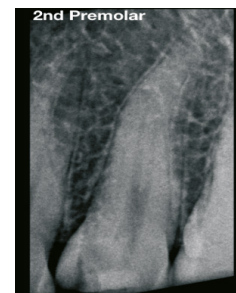Restoration done a few years before

Diagnostic findings

Inspection: mesial deep decay
Percussion test: positive
Cold test: positive with extreme sensitivity.

Diagnosis

Symptomatic apical periodontitis associated with Irreversible Pulpitis in relation to Max. Left 2nd premolar



Preoperative radiographs

“The irrigation needle is a game changer in conservative canal preparation.”

Treatment plan

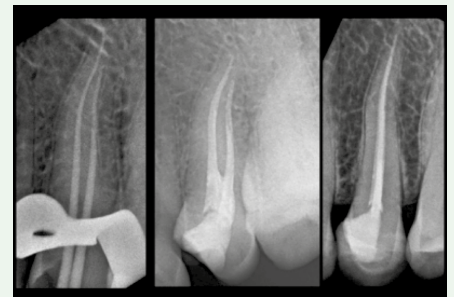
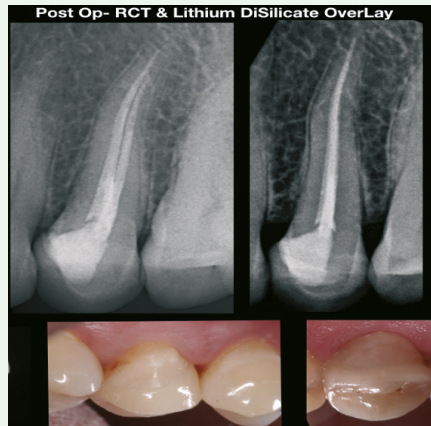Root canal therapy and cuspal coverage in a conservative approach.

Treatment: Caries driven access cavity prepared; deep isthmus refined with Start-X™ No3 ultrasonic tip. Buccal and palatal canals were located, and manual glide path achieved with #8 followed by #10 hand files with the help of Glyde chelating agent. Both the canals were multiplanar in bucco lingual direction, which could not be seen in 2D radiographs. TruNatomy® file system was used with the sequence of 3 files. Orifice modifier (#20.08v) followed by TruNatomy® glider (#17.02v) to achieve mechanical glide path and

TruNatomy® Prime (#26/.04) for shaping the canals. Continuous irrigation was done with sodium hypochlorite throughout the instrumentation with TruNatomy® Irrigation Needle and finally liquid EDTA, activated with endoactivator sonic device and obturated in the same visit.

Direct composite post endo restoration done and finally LithiumDiSilicate all ceramic cuspal coverage overlay was bonded to reinforce the tooth in a conservative approach.

Thanks to the pretreatment planning of access cavity, I have been able to preserve a healthy crown structure and structural root dentin integrity with the objective of long term tooth survival.



Postoperative radiographs with multiplanar in bucco lingual direction

“TruNatomy® system is safer, simpler, faster and effective.”



About Dr. Radmacher

Dr. Uwe Radmacher graduated in 1992 from Johann Wolfgang Goethe-University in Frankfurt where he studied dental medicine.

1995–1996 Oral surgical training with a registered surgeon.

1996–1997 microsurgical education PSI 1-3.

1995–2011 private practice Lampertheim / Südhessen and Mannheim.

Main areas: Endodontology, Microsurgery, guided Implants, high end prosthodontics.

Since 2012, he has been working in his private practice in Mannheim.

He presented various national and international lectures, workshops, publications on various topics in the field of endodontology, guided implantology, bone replacement, 3D dentistry, CAD/CAM and prosthodontics.

Coronal fractures of lower anterior teeth

About the patient

Female

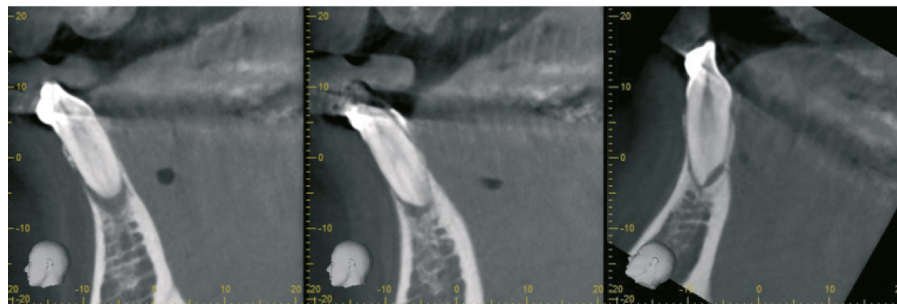
Teeth: lower anterior (41, 31,32)

The patient presented in the practice after rough contact with an antenna of a military vehicle and primary treatment after maxillary fracture with osteosynthesis plates and the loss of 3 maxillary anterior teeth. The lower anterior teeth 41,31,32 were coronally fractured, built up with composite, avulsed, repositioned and stabilized with splinting for approx. 4 weeks.

Diagnosis

To avoid any bad surprise during the treatment, canal length and depth of the beginning of canals were determined in advance thanks to CBCT.

Lengths were constantly monitored with an electronic apex locator.



Preoperative CBCT

“My objective was to be as gentle as possible on the dentin, yet still offering a proper disinfection in order not to endanger the stability of the teeth.”

Treatment plan

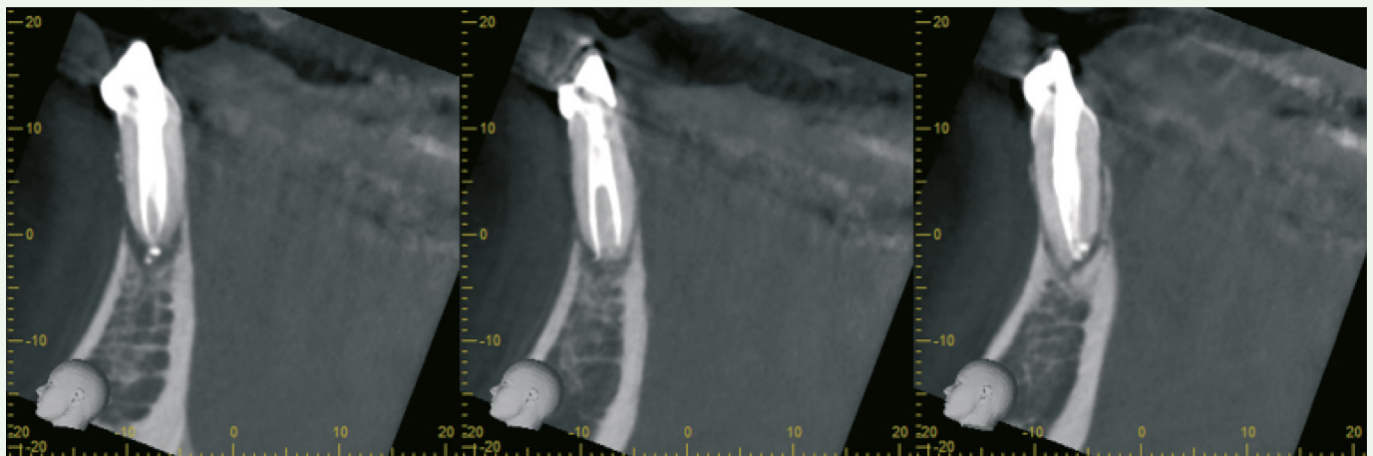
After initial preparation with the Orifice Modifier, which extended the inputs to a maximum of ISO 80 instead of the usual ISO 120, the glide path was prepared manually with a Profinder hand instrument ISO 10 and then extended mechanically with the Glider.

The preparation was performed with the TruNatomy® Prime 26/04v file.

At 31, the fracture site was prepared with the TruNatomy® Medium 36/03v and the fractured root tip was left. Irrigation was done with the TruNatomy® Irrigation Needle and allowed even in this narrow preparation to bring Sodium hypochlorite in sufficient volumes in the apical area. The solution was activated with the EndoActivator and the SiroLaser Blue to increase efficiency.

Each tooth was filled and sealed using the warm vertical technique. AH Plus® was used as a sealer, and a bioceramic sealer was used on tooth 31.

The teeth were then restored with the dual cement core-X® flow and the splint was removed. The patient was already pain-free immediately after the treatment.



Postoperative CBCT



About Dr. Abuelezz

Ahmed Hussein Abuelezz graduated with a Bachelor of science degree from Misr International University (Egypt) in 2007. He completed his Master degree of science in Endodontics, Faculty of Dentistry, Ain Shams University in 2015, and completed his PHD in endodontics from Ain Shams University as well in 2019.

He started his academic career in 2009 as a teaching assistant in Misr International University and have been a lecturer in the department of endodontics there since 2019. He started his private practice in Cairo in 2012. Today his practice is limited to restorative procedures.

A restorative approach to Endodontics

About the patient

Female, aged 21
Tooth: Lower right first molar

Chief complaint

Patient was having spontaneous pain which increases with cold stimuli related to the lower right side.

Notable dental history

None

Diagnosis

Upon examination, there was a caries lesion related to the lower right first molar. Radiographic examination revealed proximity of the lesion to the pulp horn and combining it with the chief complaint, a final diagnosis of chronic irreversible pulpitis was concluded.

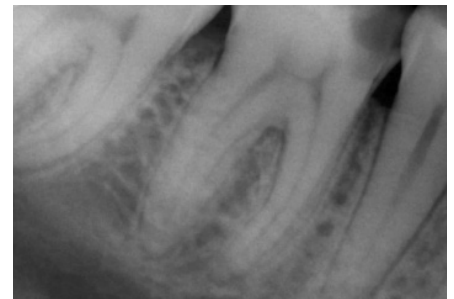

Figure 1: Preoperative X-Ray

“I chose TruNatomy® to be able to preserve as much dentin as possible to overcome occlusal load and increase the longevity of the tooth.”

Treatment plan

Access cavity was done as conservative as possible. TruNatomy® was the system of choice due to the young patient's age. We needed to preserve dentine as much as possible to increase the tooth ability to overcome occlusal load and increase the longevity of the final restoration. The initial file was K-file #15 in the mesial canals and K-file #25 in the distal canal. This made it possible to use that system as the TruNatomy® Prime would sufficiently clean the mesial canals and the TruNatomy® Medium would be more than enough for the distal canal. The activation of the irrigation solution was done using ultrasonic tips in each canal separately. Warm vertical compaction was done using Gutta Smart system with the TruNatomy® Comform Fit™ gutta percha as master cones and AH+ sealer.

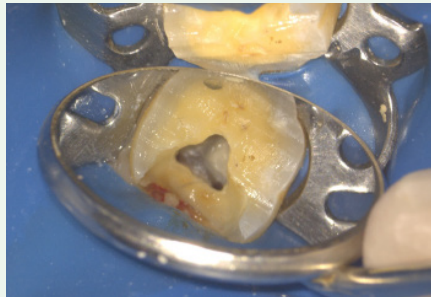


Figure 2: Conservative access cavity

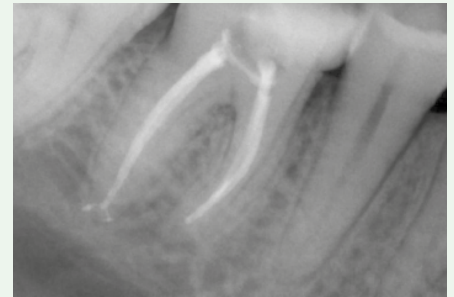


Figure 3: Postoperative X-Ray

After seeing the sealer going through the lateral canals in the distal root, we were confident that the activation of the irrigation solution was enough and that highlights its significance. A very thin layer of SDR was added to the floor to have a smooth surface for the endocrown.



About Dr. Clauder

Dr. Thomas Clauder graduated in 1994 at the University of Hamburg in dental medicine.

From 1997 private practice in Hamburg, Germany

1999-2001 International Program, Department of Endodontics - University of Pennsylvania, USA (Prof. Dr. Syngcuk Kim).

2001 Certification in Micro-endodontics and Endodontic Microsurgery - University of Pennsylvania, USA.

2002 Limitation to Endodontics and endodontic Microsurgery.

He is a national and international lecturer and author of publications.

A conservative approach for a premolar with three thin roots

About the patient

Male
Tooth: Tooth 14 (upper premolar)

Chief complaint

Fistula

Notable dental history

None

Diagnosis

Pulp necrosis, chronic apical periodontitis associated with a fistula.

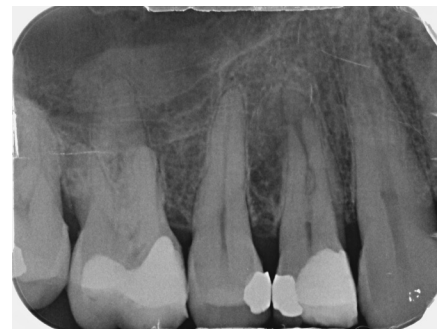

Figure 1: Preoperative radiograph from the referring dental clinic shows an extensive apical lesion

“TruNatomy® offers a conservative approach that is ideal for thin roots.”

Treatment plan

Root canal treatment with immediate adhesive restoration of the tooth, followed by definite restoration with a crown by referring dentist.

The CBCT showed an extensive destruction of the bone with a perforation on the buccal side and a premolar with three very slim roots. After accessing the tooth under the operating microscope, TruNatomy® was chosen to prepare the delicate anatomy of the tooth up to TruNatomy® Medium. Irrigation was enhanced using laser activation of EDTA 17% and 3% sodium hypochlorite according to the sweeps protocol. Calcium hydroxide was placed in the canals and the tooth closed with a temporary restoration. During the second appointment, the fistula was closed. After repeated laser activated disinfection, the tooth was obturated using the warm vertical compaction technique and restored immediately with an adhesive build up.

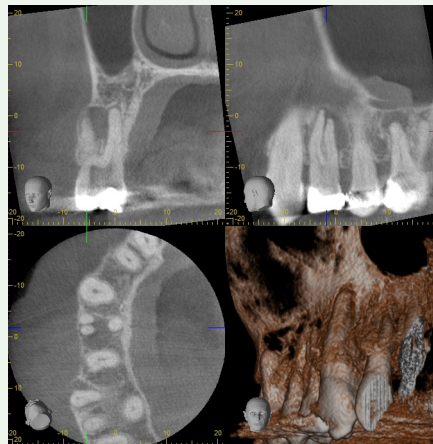


Figure 2: CBCT shows an interesting anatomy of a premolar with three very slim roots

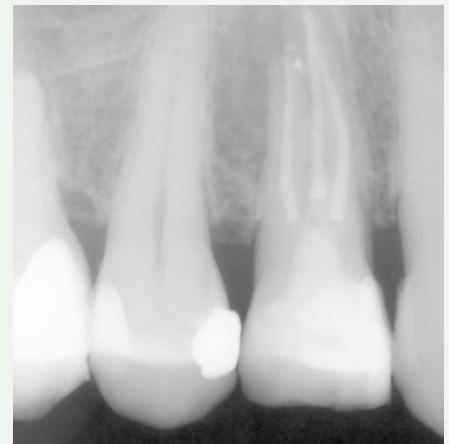
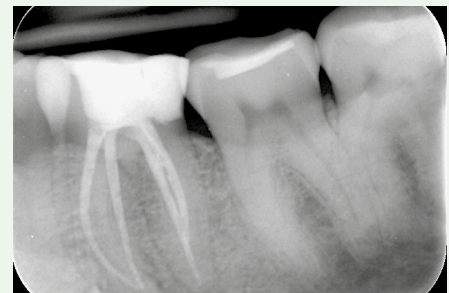
Figure 3: Canal orifices in the pulp chamber



Figures 4: Postoperative radiograph showing conservative shaping technique ideal for the tiny roots



About Dr. Rechenberg

Dr. Rechenberg graduated in Germany from the University of Göttingen, School of Dental Medicine in 2005. After finishing dental school he worked for the University of Göttingen, and for the University of Zürich, where he received his doctoral degree in dentistry (Dr. med. dent.).

In 2012 he completed the postgraduate endodontic program at the University of Zürich and was noticed as a board certified member of the Swiss Society of Endodontology (SSE).

He received the lecturer title (Priv. Doz.) from the University of Zürich in 2017 where he currently serves as senior lecturer and the co-head of the postgraduate endodontic program.

Dr. Rechenberg teaches advanced endodontic training courses and is a national and international invited lecturer in the field of endodontics.

Moreover, he maintains a clinical practice in Zürich, limited to root canal therapy and microsurgical endodontics (www.endodontie.ch).

Management of a pulp necrotic maxillary molar with acute apical abscess – a case of root canal obliteration

About the patient

Male, aged 71

Tooth: Referred by general practitioner for root canal treatment of tooth 16

Dental history

The tooth had been restored more than 2 decades ago. Suddenly, presence of swelling, spontaneous pain, and pain on biting.

Diagnostic findings

Localized swelling of the buccal gingiva in close approximation to the mesiobuccal root tip of tooth 16. Tooth non-responsive to sensitivity testing. Radiographic presence of pulp canal obliteration and apical periodontitis (Fig. 1).

Diagnosis

Pulp necrosis with acute apical abscess tooth 16.

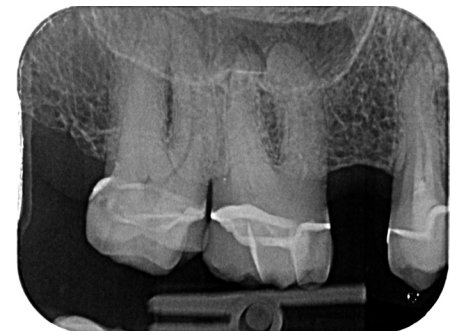

Figure 1: PreOp radiograph showing signs for apical periodontitis and root canal obliteration on tooth 16

“If I can achieve successful clinical results using a more conservative root canal instrumentation, I do not see much sense in using greater tapered one.”

Treatment plan

Negotiation of root canals and cervical dentin conserving shaping: palatal, distobuccal, mb1 TruNatomy® Medium (36.03); mb2: TruNatomy® Prime (26.04), until fusion with mb1. Irrigation with 3% sodium hypochlorite (Fig. 2), passive ultrasonic activation, smear layer removal with 17% EDTA, and intracanal dressing. Signs and symptoms subside after treatment. Two weeks later, root canal obturation using warm vertical compaction including temporization (Fig. 3, 4). The patient was sent back to the referring dentist for the final restoration.

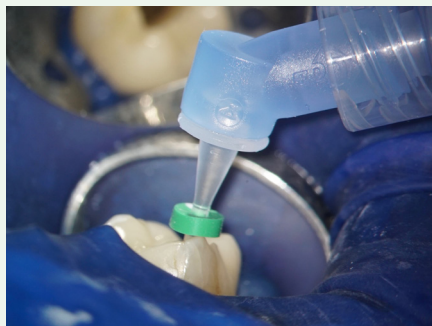

Figure 2: Controlled root canal irrigation to working length using the TruNatomy® irrigation needle

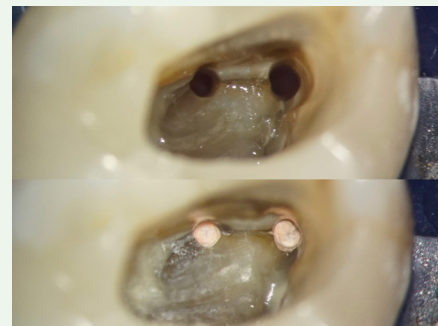


Figure 3: Mesio Buccal root canal system after cleaning, shaping and obturation

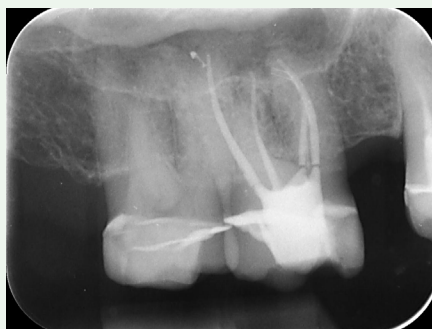

Figure 4: PostOp radiograph showing sufficient root canal obturation and temporization



About Dr. Ruiz

Dr. Xavier-Fructuós Ruiz graduated from dentistry at the International University of Catalunya (UIC) in Barcelona, Spain. He also obtained his Master degree in Endodontics as well as a Master Degree in Dental Research from the same university. In 2018 he was a visiting doctoral researcher at ACTA (Amsterdam, The Netherlands).

In 2017, Dr. Ruiz won the best clinical case presentation award at the Biennial Congress of the European Society of Endodontology (Brussels, Belgium). In 2018, he won the best scientific article published in 2017 at the XXII National and IX International Congress of the SEOC (Seville, Spain). In 2020, he received the Journal of Endodontics Publication Award 2019 for the best published systematic review.

Dr. Ruiz is an associate professor at UIC and has contributed, as an author, to scientific publications related to endodontics in national and international journals with high-impact factor. He is an active member of the Spanish Society of Endodontics (AEDE) and a specialist member of the European Society of Endodontology (ESE). Furthermore, he gives lectures in national and international congresses. Since 2020, he has been a Style Italiano Endodontics Silver Certified Member.

Management of a complex maxillary first premolar with a double curvature.

About the patient

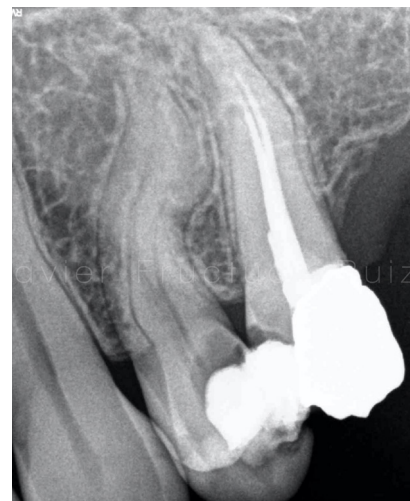Patient age: 35
Tooth: First premolar

History of complaint:
Pain when drinking cold beverages.

Notable dental history
None

Diagnosis

Tooth decay causing a symptomatic irreversible pulpitis with normal periapical tissues.



Preoperative radiographs

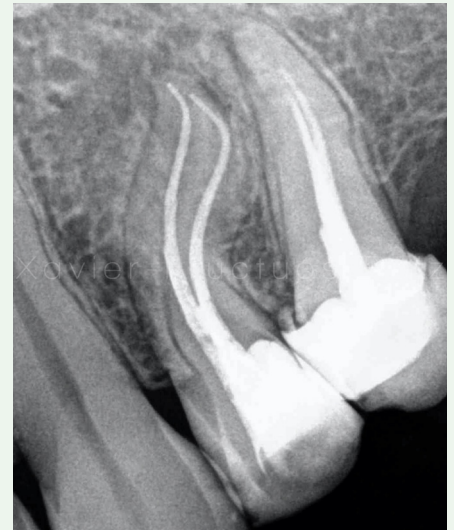“TruNatomy® system allows me to treat challenging cases in a conservative approach, minimizing the risks of having an instrument separation.”

Treatment plan

Root canal treatment followed by a direct composite restoration.

After tooth decay was removed, access cavity was performed and modified with an ultrasonic tip (StartX n°3). TruNatomy® Orifice Modifier was used to perform a coronal preflaring. After that, patency was achieved and working length was determined with a manual K-file 10 in both canals (buccal and palatal).

TruNatomy® Glider was used to perform the glide path and the final instrumentation was carried out with the TruNatomy® Prime file (26.04). NaOCl 4.25% was used for irrigation followed by a sonic activation with Endoactivator™. Finally, a continuous wave of condensation technique was chosen to obturate both canals and a direct composite restoration was performed using SDR™ and Ceram.X universal™.



Postoperative radiograph

dentsplysirona.com/trunatomy



All products except
Irrigation Needle

Maillefer Instruments Holding Sàrl
Chemin du Verger 3, CH-1338 Ballaigues, Switzerland
Phone: +41 (0)21 843 92 92
endo@dentsplysirona.com
dentsplysirona.com



EC REP

2797

DENTSPLY DeTrey GmbH
De-Trey-Straße 1, 78467 Konstanz,
Germany

Irrigation Needle

Produits Dentaires SA
Rue des Bosquets 18, CH-1800 Vevey, Switzerland
pdsa.ch

1639

PD Dental EU
Thonon-les-Bains 74200, France

