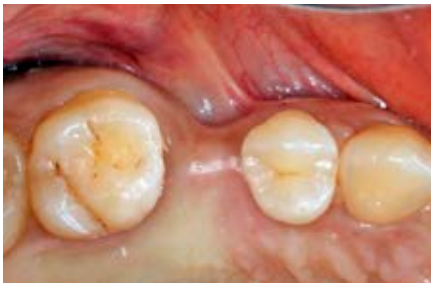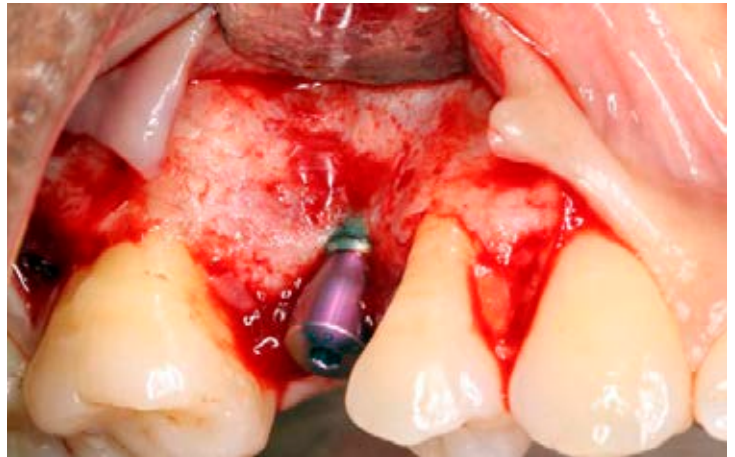




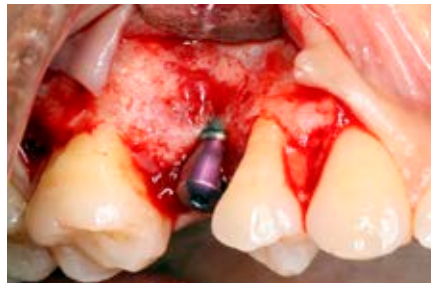
Rodrigo Neiva, DDS, MS
Philadelphia, PA

Correction of buccal ridge deficiency at implant second stage surgery

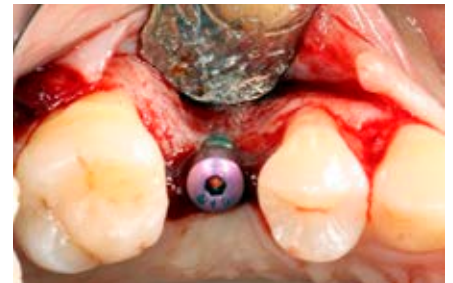32-year-old female presented with tooth #4 missing. Tooth had been extracted 5 years before initial examination. A 3.6 x 13 mm implant was placed in conjunction with GBR to correct horizontal alveolar bone deficiency. At second stage surgery, volumetric soft tissue deficiency and thin buccal plate were found. Soft and hard tissue augmentation were performed using a double-layered OSSIX® Volumax scaffold, without bone grafting materials.



1. Occlusal view of #4 implant before surgery to uncover the implant. Soft tissue volume deficiency detected.



2. Flap elevation showing that the buccal plate was thin, but still present.



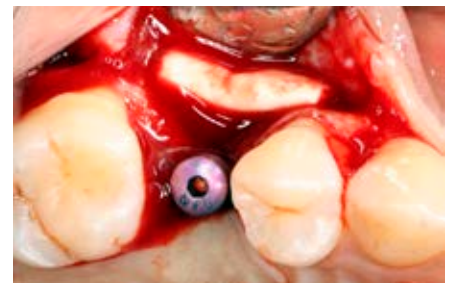3. Occlusal view illustrates ridge deficiency that would result in poor esthetic outcome of the future implant restoration.



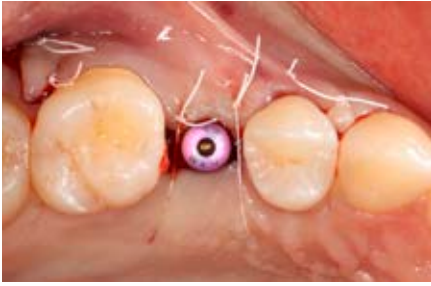4. OSSIX Volumax (25x30mm) after hydration in sterile saline.



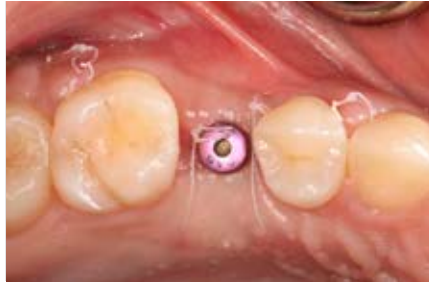5. OSSIX Volumax folded in half for additional tenting and tissue thickness.



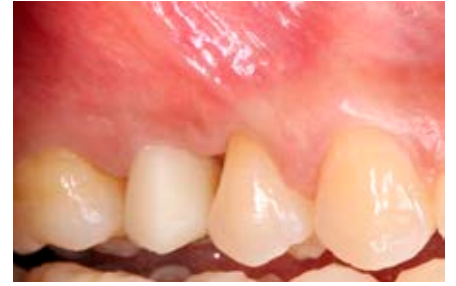6. OSSIX Volumax adapted for optimal ridge without bone graft.



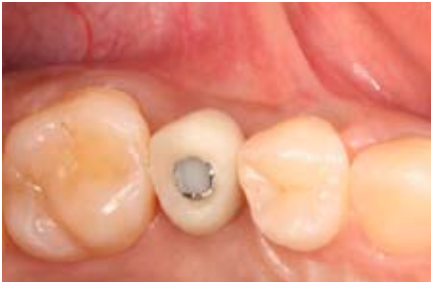7. Buccal flap positioned and sutured with 4.0 PTFE sutures.



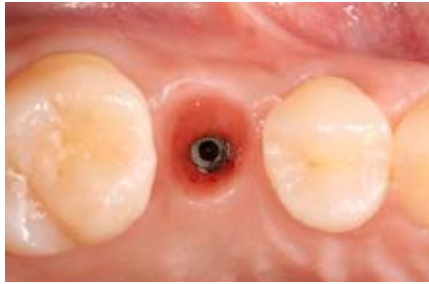8. 2-week post-op showing optimal wound healing and ridge contours.



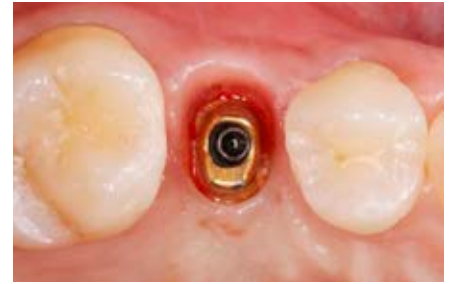
9. Provisional restoration was installed at 30 days to develop soft tissue profile.



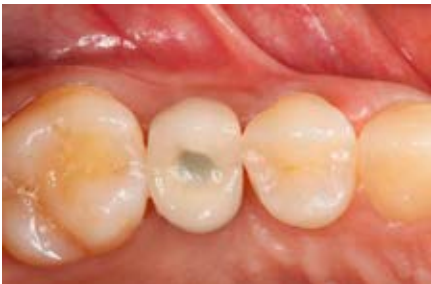10. Occlusal view at 3 months before final impressions.



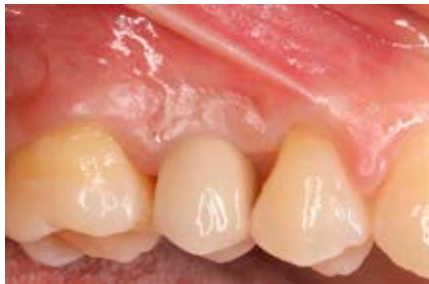11. Occlusal view at 5 months showing stable results and soft tissue health.



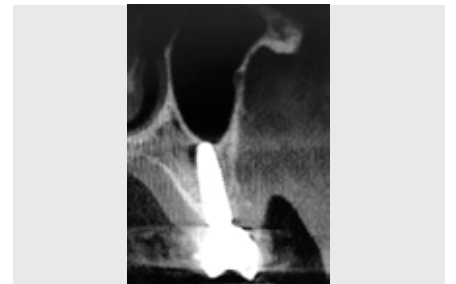12. Abutment adaptation to the developed soft tissue profile.



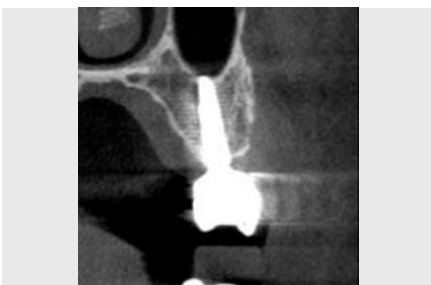13. Follow-up at 6 months showing stable results after final restoration.



14. Buccal view showing excellent esthetic result with OSSIX Volumax.



15. 6 months CT scan. Original bone and OSSIX Volumax ossification visible.



16. 3 year follow up. Continued OSSIX Volumax ossification visible.

This case report is made by an independent dental professional using Dentsply Sirona products.

www.dentsplysirona.com

