



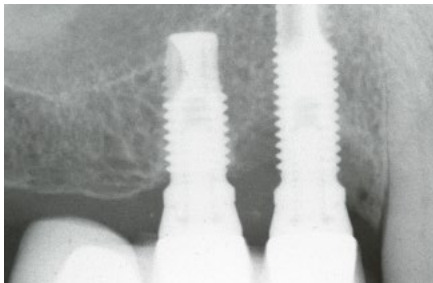
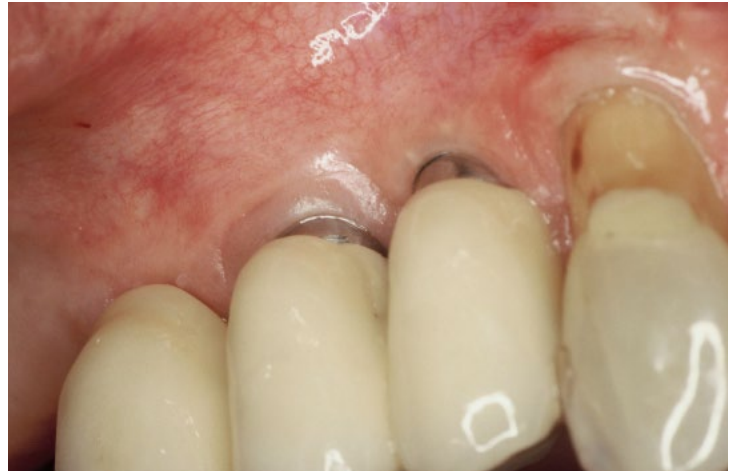Ann-Marie Roos Jansåker
Odont. Dr.
Specialist in Periodontology
Kristianstad, Sweden

15-year follow-up of peri-implantitis treatment and bone regeneration with Algipore®

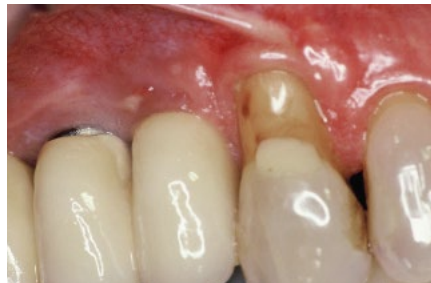A 70 year old woman (healthy and former smoker) was referred to the clinic with radiographic bone loss around implant 14. The implant had been in place for 5 years.

Flap elevation surgery was performed with debridement of the infected site. The 3-wall bone defect was completely filled with Algipore, an algae-derived graft material for bone regeneration. Supportive therapy was conducted every 3rd month and maintenance was continued for 15 years.

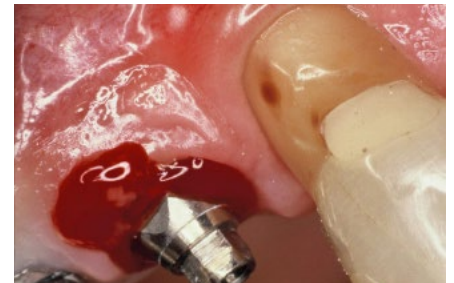
At 10 years post-treatment, there were no deep pockets, there was only minimal bleeding at one site, and the marginal bone levels were stable.



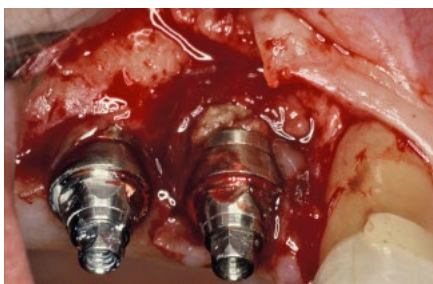1. Radiograph showing the large bony destruction around implant in position 14. Note that implant in position 15 is not affected by bone destruction.



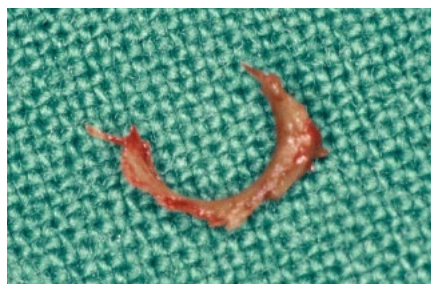2. Clinical signs of swelling of the mucosa and pus at the affected implant in position 14. Plaque index 35%.



3. Bleeding on probing (pockets 5-6 mm) and pus. **Diagnose:** Peri-implantitis.

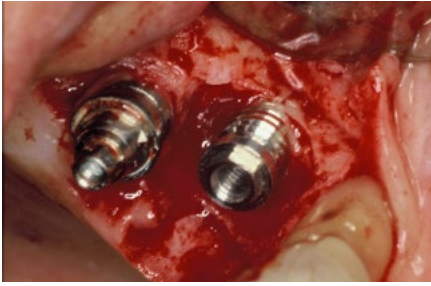


4. At surgery by flap elevation, calculus and granulation tissue is detected.

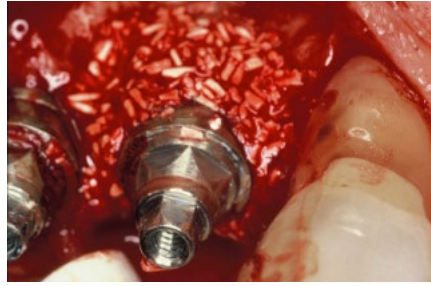

5. Removed calculus.

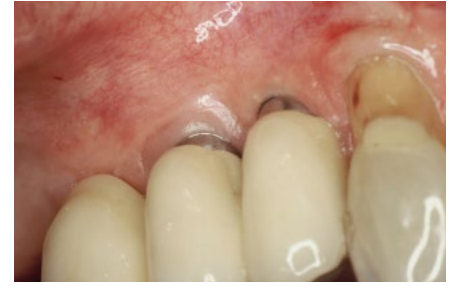"I have many years experience of Algipore and I am very fond of the material. It is easy to use and it seems to regenerate bone in defects around implants with long time stable results."



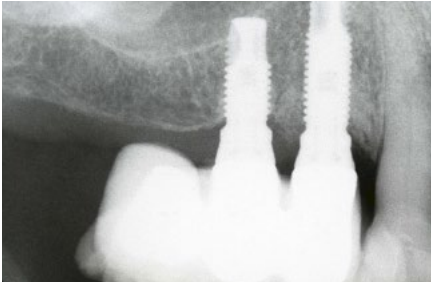
6. 3-wall bony defect cleaned from granulation tissue and calculus. Note that the neighbouring implant is not affected with any bone destruction.



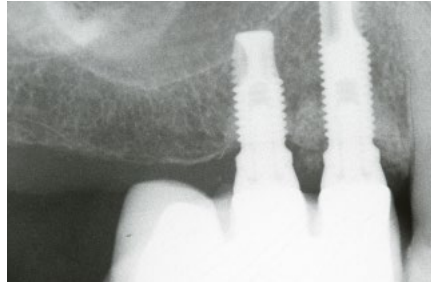
7. Complete defect filled with Aligpore before tension free flap suturing. Post operative care consisted of rinsing with chlorhexidine for 2 weeks, then the sutures were removed. An oral hygiene control was performed 5-6 weeks after surgery, with a maintenance program every 3rd month.



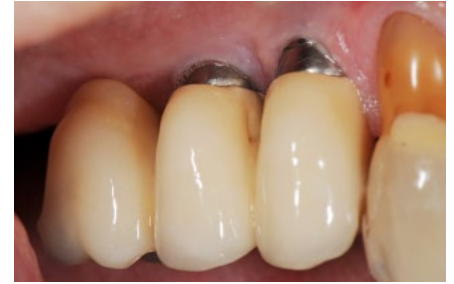8. 1 year follow up. Healthy mucosa, but also recessions. No bleeding on probing and pockets 1-2 mm



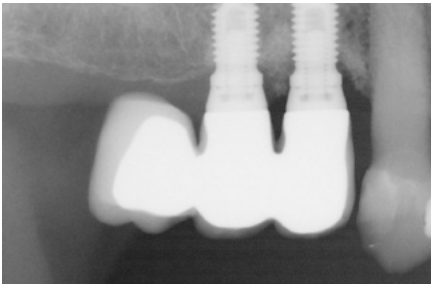
9. 1 year radiographic follow-up. Note the defect fill at implant 14.



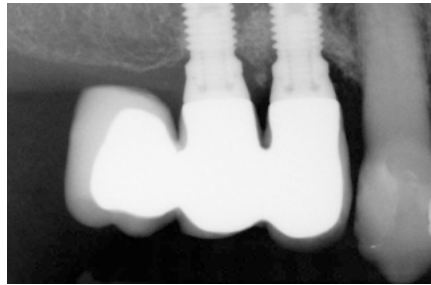
10. 5 year radiographic follow-up. Note the defect fill at implant 14. The regenerated defect seems more radiopaque.



11. 10 years follow-up. The patient is now over 80 years old. Minimal plaque on the mesiobuccal side otherwise good oral hygiene, no bleeding on probing and pockets 1-2 mm. Plaque index during follow-ups at 5-10%.



12. 10 years radiographic follow-up. Minimal bone loss at the implant.



13. 15 years radiographic follow. Stable bone levels compared to 10 years. The patient is 85 years old and still continues with the maintenance programme.

Treatment procedure:

Initially: The patient was informed and educated in the etiology of peri-implantitis and good oral hygiene habits. Systemic antibiotics (amoxicilline +metronidazole) were prescribed

for 10 days starting the day before surgery.

Surgery: The prosthesis was removed. Flap elevation was followed by mechanical debridement of calculus and granulation tissue with hand

instruments. The implant surface was cleaned by rubbing the surface with gauze soaked in 3% peroxide, then rinsing with saline solution before filling the bone defect with bone graft material, Aligpore.

Maintenance: every 3rd month.