

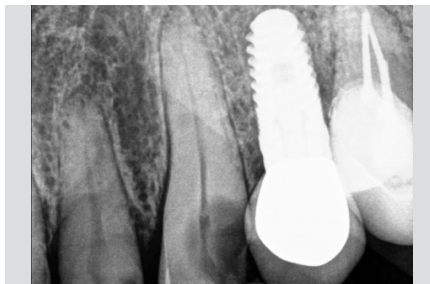
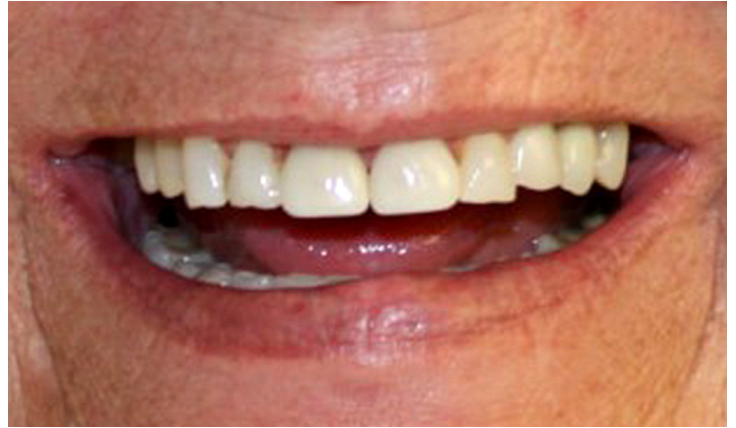

Daniel Butterman, DDS  
Butterman Dental, Centennial, CO

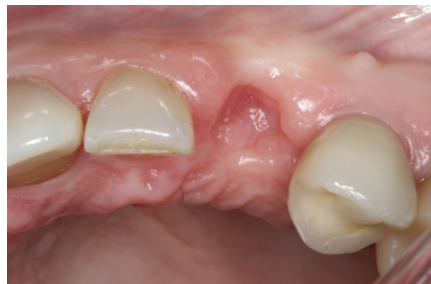## Azento™

### Tooth #11 replaced with Astra Tech Implant System® EV using Azento™

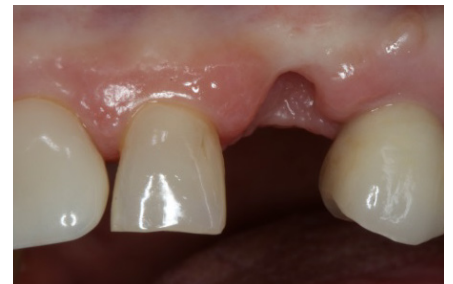The patient is a 54-year-old female with severe xerostomia resulting in gross caries on tooth #11. The restorative prognosis was poor and she elected to have the tooth extracted and replaced with an OsseoSpeed® EV implant utilizing the Azento solution. The extraction site was allowed to heal for 3 months after the DFBA bone graft. Guided surgery was performed in order to position the implant in an ideal restorative position for a screw-retained restoration. The immediate provisional was used to ideally shape the gingiva from the day of surgery and to provide her with an esthetic provisional. The provisional was taken out of occlusion and the patient was instructed to use this for smiling only.



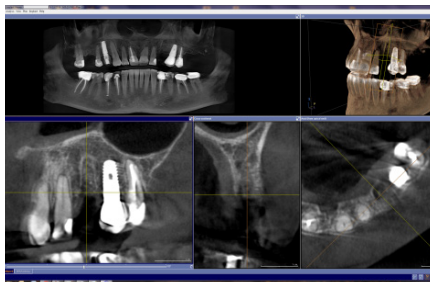
1. Pre-operative radiograph of tooth #11 showing gross caries into nerve and extending beyond the attachment level. Crown lengthening would compromise adjacent tooth and implant.



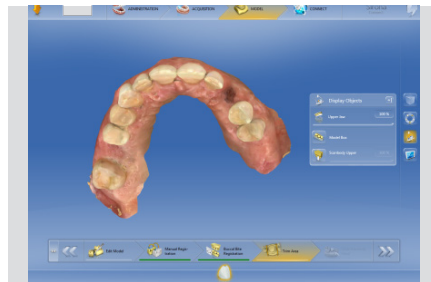
2. Pre-operative image of healed ridge following tooth extraction and bone grafting.



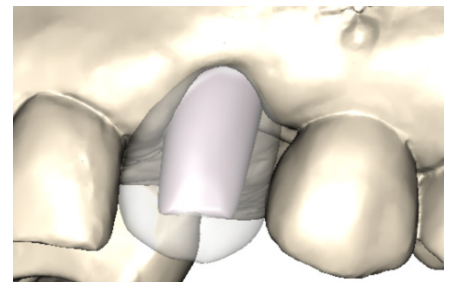
3. Facial view of edentulous space.



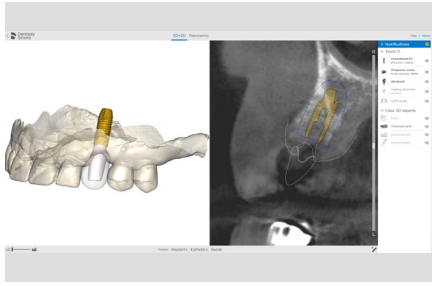
4. View of patient CBCT scan in Sidexis software.



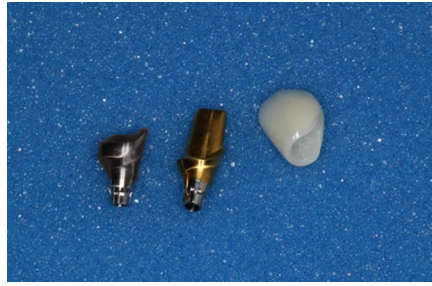5. CEREC intraoral scan of treatment arch.



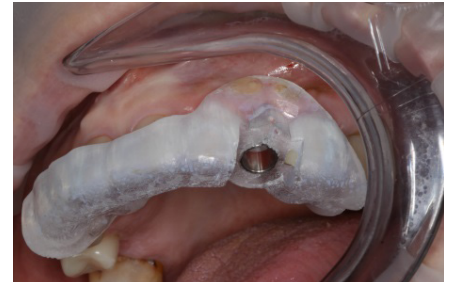6. Design proposal of the patient-specific Atlantis® Abutment and immediate provisional shown in Azento case viewer.



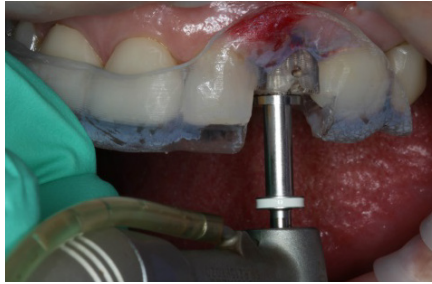**7.** An implant and restorative treatment proposal was designed using the patient's intraoral & CBCT scans. The Azento case viewer displayed the treatment proposal in both 2D and 3D, with convenient presets to view the implant, guide and esthetic mode.



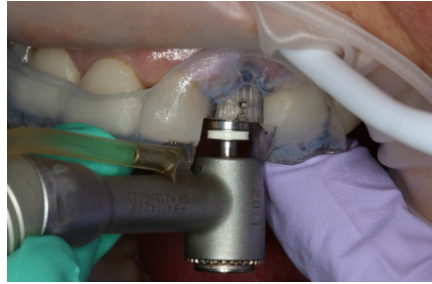**8.** Close-up image of Atlantis Healing Abutment, Atlantis Abutment and provisional crown. Note the emergence profile of the custom healing abutment mimics the patient-specific Atlantis Abutment.



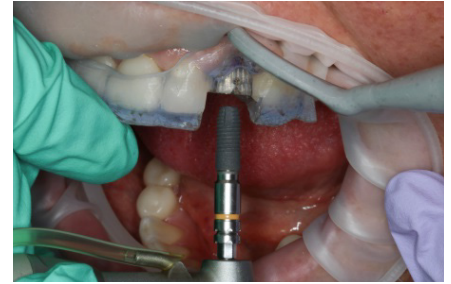
**9.** The tooth-supported Simplant SAFE Guide was placed in the patient's mouth. The guide is designed to fit retentively and has an index marking to align the rotational position of the implant.



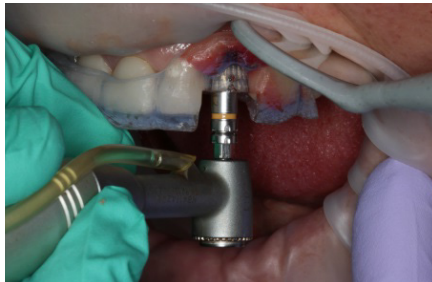**10.** Keyless guided surgery with sleeve-on-OsseSpeed EV system drill.



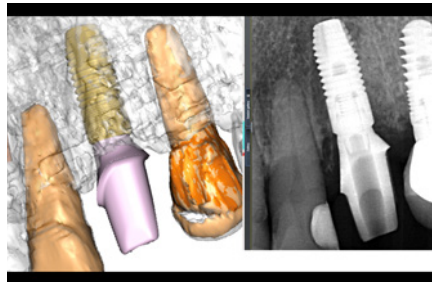
**11.** Full length drills (sleeve-on-drill system) with mechanical depth stop were used for the osteotomy preparation.



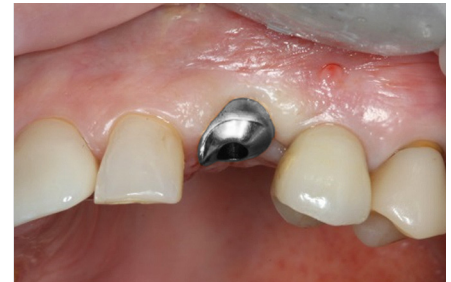**12.** Insertion of OsseoSpeed EV implant through Simplant SAFE Guide.



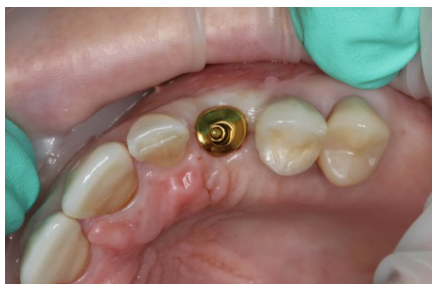**13.** Note alignment of index marking on guide and notch on implant driver. This ensured that the Atlantis Abutment was in the proper position for the delivery of the provisional on the day of surgery.



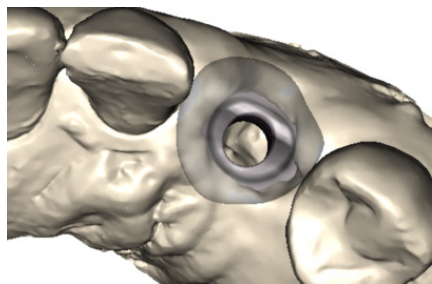
**14.** Azento proposal prior to surgery on the left. On the right, radiograph of OsseoSpeed EV implant and Atlantis Abutment.



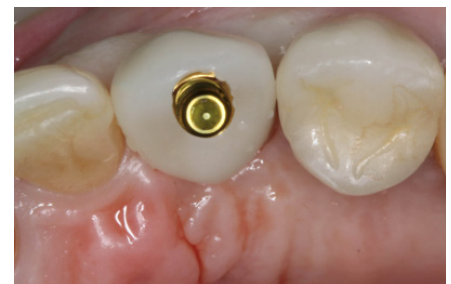**15.** The Atlantis Healing Abutment, which was designed with the same emergence profile of the final Atlantis Abutment, was also provided in the event the case wasn't immediately provisionalized.



**16.** The Atlantis Abutment, in gold-shaded titanium, is seated in one-position-only for a simple restorative procedure.



**17.** Side-by-side comparison of Azento treatment proposal and post surgical results of guided implant and restorative procedure.



This case report is published as an inspiration for you as a clinician/technician and not necessarily as a recommendation from Dentsply Sirona.