

Pulpotomy and the treatment of dentin hypersensitivity with a 970 nm diode laser

Jesko Gärtner

ABSTRACT

This article presents two indications for laser treatment which rarely occur in the dental practice: The desensitization of dentin hypersensitivity and pulpotomy. Pulpotomy refers to the removal of the coronal pulp while preserving the vital radicular pulp, an indication that is mainly limited to pediatric dentistry. This applies to the exposed pulp of primary teeth that has suffered traumatic injury or been damaged by deep caries, as well as that of not fully developed permanent teeth. The former, in particular, are subjected to this treatment because a pulpectomy with subsequent endodontic treatment of the primary tooth is problematic; in the latter, the tooth has a chance to develop fully through the remaining radicular pulp. In the following, pulpotomy is discussed within the context of the endodontic treatment of 60 teeth in the pediatric dental practice and their clinical recovery. Hypersensitivity among the patients of every dentist is prevalent in both sexes and is experienced as severe, sharp pain after chemical or tactile stimulation of the tooth. The causative factors are assumed to be overreaction and misinterpretation of these stimuli with regard to the healthy tooth. The formation of the main defects on the affected teeth is multifactorial—this may be causally related to the occurrence of erosive, mechanical or abrasive processes.^{1,24} Today, these reactions are explained via the displacement model of the fluid in the dentinal tubules. The cervical region of canines and premolars are the most affected. Until now, the treatment of hypersensitivity was done with active ingredients, like nitrates and fluorides.² This paper shows the management and results in the treatment of hypersensitivity, which are based on the treatment of these patients with a diode laser (SIROLaser Advance). The procedure was done on 47 teeth in 16 patients with a significant reduction in pain. In addition to professional dental treatment, changes in oral hygiene at home need to be discussed with the patient, appropriate tools have to be provided and understandable instructions given.

KEYWORDS

Diode laser, SIROLaser, 970 nm, pulpotomy, dentin hypersensitivity

Introduction

Pulpotomy

Primary teeth should be preserved as long as possible until their physiological loss in order to ensure chewing function and normal bite development as well as for phonetic and esthetic reasons.³ In the case of deep caries, endodontic treatment is often necessary if indirect capping is not possible. Indications are:

- No pain or mild pain
- No more than one third of the root is resorbed
- Restoration of the tooth must be possible
- Vitality of the remaining radicular pulp
- Immobility of the tooth.

The pulpectomy on the primary tooth is limited due to different factors:⁴

- Duration of treatment
- Condition of root canal is difficult to determine
- Damage to the successional tooth germ due to over instrumentation. Overpacking or transferring infected material beyond the apex

- Root filling material often withstands physiological resorption
- Danger of fracture gracile roots.

Thus, if possible, the aim should be only partial amputation of the pulp.

The long-term preservation of a permanent tooth is only possible if it has a proper crown-to-root ratio and the dentin walls are sufficiently stable to ensure normal function. After endodontic treatment of carious, young permanent teeth with not yet fully developed roots, apexogenesis and normal root development is only possible if the radicular part of the pulp remains intact.⁵ Also in this case, a partial pulpotomy is to be performed in the caries profunda treatment with vital pulp or reversible pulpitis if the pulp chamber was opened and indirect pulp capping is not possible. After opening the pulp chamber and its partial removal, hemostasis is crucial; the bleeding should stop within a few minutes. On the one hand, coagulation at the amputation site promotes inflammation, prevents the formation of a hard tissue bridge and facilitates internal resorption processes leading to pulp necrosis; on the other hand, prolonged bleeding indicates inflammatory changes in the

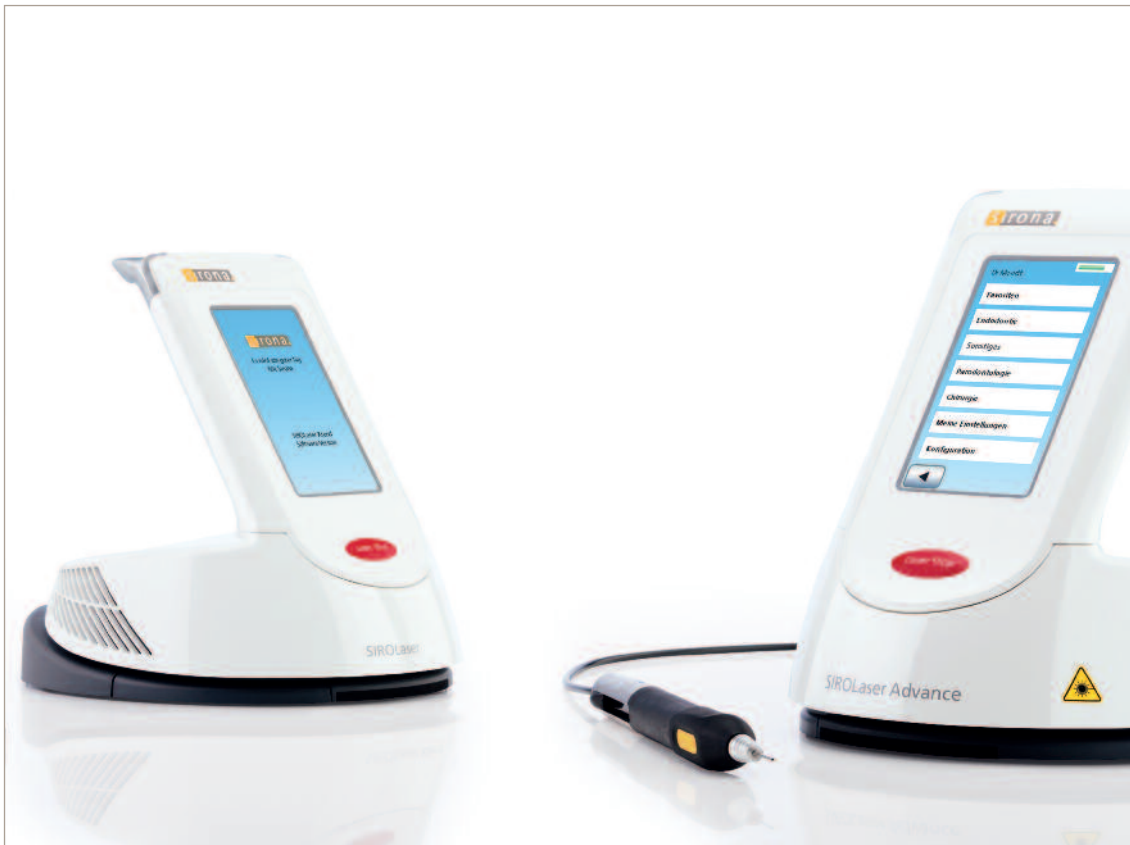

Fig. 1: SIROLaser Xtend and SIROLaser Advance.

pulp. Amputation of the coronal pulp is often performed with diamond instruments under water cooling. Along with formocresol as a pulpotomy medicament, which is a potential mutagen⁶, electrosurgical devices⁷, ferrous sulfate⁸ and lasers are also used due to their hemostatic effect. The first applications of laser in pulpotomies were with the CO₂⁹, Nd:YAG¹⁰ and Er:YAG lasers¹¹. The 980 nm diode laser was also the subject of a randomized split mouth study by Saltzman et al.¹², in which a conventional formocresol-zinc oxide eugenol pulpotomy was compared to a diode laser pulpotomy with mineral trioxide aggregate (MTA). The study showed that in a 15-month observation period both methods were equivalent.

Desensitization of dentin hypersensitivity

Despite the large number of patients with dentin hypersensitivity, there is relatively little understanding of the clinical conditions. Nevertheless, the prevalence of this condition continues to increase. This can be attributed to the overall improvement in oral health, which means that patients retain their own teeth for a much longer time and to a greater extent. In current studies, a prevalence of up to 57 % is given for dentin hypersensitivity without periodontal diseases. In patients with periodontal diseases of different etiology, the figures are 60 to 98 %.¹³ The most frequently affected patients are between the ages of 23 to 55—middle-aged patients. The discomfort that patients with dentin hypersensitivity experience on a daily basis often results in limited oral hygiene in order to prevent the stimulation of

pain. Successful treatment depends on eliminating the causal factors to the greatest extent possible, in order to make good and successful oral hygiene possible again as an important component of an efficient prophylaxis against this condition.¹⁴ According to the current state of studies in this area, there are no long-term satisfactory treatment approaches available.

The dentin surfaces of the buccal portion of the tooth in healthy tissue are covered with tooth enamel or cement and there is no dentin hypersensitivity. Recession, abrasion, erosion, attrition or habit results in the removal of the protective structures and exposure of the hypersensitive tooth. Patients describe the pain after physical, tactile or chemical stimulation as short, severe and sharp.^{13,15} In terms of intensity, manifestation and characteristics, there is no similarity to the sensation of pain of other diseases—in addition, the pain is not related in any way to a prosthetic restoration or carious lesions. An accepted explanation of the causes of dentin hypersensitivity is Brannström's theory that movement of the fluid in the dentinal tubules occurs due to a chemical, osmotic, physical or mechanical stimulus. This mechanism activates the pain fibers in the tooth pulp.^{16,17,18} However, the exact physiological mechanisms in the pulp are not conclusively known and have not been fully assessed. A decisive factor is certainly the number of dentinal tubules in the affected area. Despite undergoing treatment for dentin hypersensitivity by means of closing the dentinal tubules, the patients are often not pain free; as an extension of Brannström's theory, this

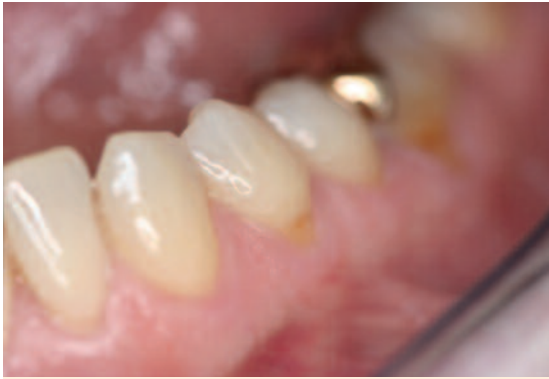

Fig. 2: First premolar with exposed dentin.

means that inflammatory processes of the tooth pulp also play an important role. Nevertheless, the existence of bacteria is not the primary factor.¹⁴

Besides the aforementioned reasons for dentin hypersensitivity, other factors may also play a significant role. Wedge-shaped defects resulting from incorrect brushing techniques accompanied by up to 90 % dentin hypersensitivity, bleaching, uneven loading and inadequate restoration need to be checked in order to make a reliable diagnosis. Overall, there are multiple factors contributing to dentin hypersensitivity. Along with a reliable diagnosis and elimination of patient-related risk factors, clinical management of dentin hypersensitivity must interrupt the hydrodynamic mechanism and reduce tooth pulp inflammation.¹⁹ For some time now, desensitizers have been used to close the dentinal tubules. These materials include primer systems, dentin adhesives and toothpastes. In addition, the treatment approaches pursued are soft tissue management, fillings and, as a last resort, endodontic restoration of the tooth.

Criteria for these desensitizers and treatment approaches according to Grassmann (1935) and Renton-Horpes (1992) that are valid even today are:^{16,17,18}

- No pulp irritation
- No soft tissue irritation
- Painless application
- Uncomplicated handling
- Quick effect
- Adequate and long-lasting effect
- No side effects.

No known substance can meet all these requirements—mainly the criteria of a long-lasting effect and the related freedom from pain are only partially met. The application of the materials described above has an average efficacy of 4 weeks. Consequently, only an acute relief of the clinical situation can be achieved, but no long-term improvement. The further development of toothpastes with additives such as nitrates and bio-glass will have to be observed in the future. These additives have the potential of providing the patient with significant advances in the way of aids for oral hygiene at home.

In modern dentistry, laser can offer great support as a technology in the treatment of dentin hypersensitivity to provide an adequate, lasting form of treatment. It can be used with or without topical applicators. Many studies have clearly elaborated that the long-term effects of laser light irradiation are superior to previously used treatment mechanisms. Due to the complexity of the laser treatment, it must be professionally done and only by a dentist. It is imperative to notice the different interactions of the tissue structures as well as the biophysiological tissue changes depending on the wavelength and kind of laser (active medium).

Use of a low level laser (diode laser) creates inhibition of cyclooxygenase, biostimulation linked to the additional ATP synthesis and pain relief.^{20,21} Irradiation with a diode laser with a power output setting of up to 60 mW does not result in any morphological surface changes of the dentin structures.^{16,17,18} In contrast, a middle output laser (Nd:YAG, Er:YAG or CO₂ laser) causes morphological changes in hard tissue. A therapeutic effect with this type of irradiation is a sealing of the dentinal tubules. Nevertheless, both classes of lasers increase treatment efficacy in direct comparison to the application of different desensitizers.^{16,17,18} Management of dentin hypersensitivity with a diode laser has been investigated in many studies and very good results regarding its efficacy have been confirmed. According to the present situation of studies in the area of irradiation with different laser systems, the diode is one of the best-researched forms of clinical treatment.

The treatment of the patients described in this paper was performed via irradiation with a diode laser at a wavelength of 970 nm (SIROLaser Advance, Sirona) with the additional application of fluorides. In addition to biostimulation processes in the form of the bioactivation of odontoblasts for tertiary dentin formation, photobiomodulation as well as a “melting effect” takes place. This results in crystallization of the dentin and simultaneous coagulation of the fluid medium, e.g., fluoride or other desensitizers in the dentinal tubules. The rate of successful treatment is 65–98 %.²²

No side effects in the respective treatment situations have been observed up to now.

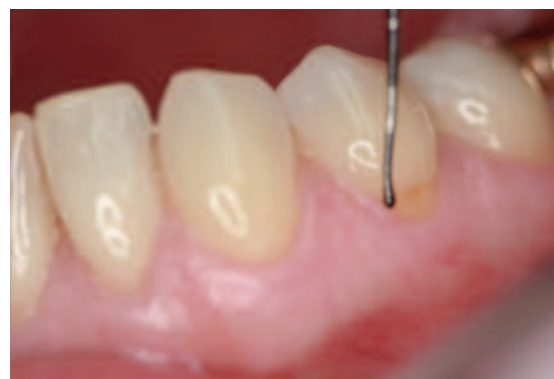

Fig. 3: Tactile stimulation with a WHO periodontal probe.

Materials and Methods

Laser

The SIROLaser Advance (Sirona Dental Systems, Bensheim, Germany) (Fig. 1) is an infrared diode laser with a wavelength of 970 nm and a power output of 0.5–7 W in continuous wave and pulsed mode. The frequency of the laser in pulsed mode can be set to between 1 Hz and 20,000 Hz. The duty cycle—the ratio of pulse duration to reciprocal value of the frequency setting— can be set between 1 % and 99 %. The treatment parameters of the manufacturer were selected for each treatment; the exact values can be found for the respective indications. For a pulpotomy, a 200 mm fiber was used and a fiber with a diameter of 320 µm was used for desensitization.

Pulpotomy

In the last four years, a pulpotomy was performed with the SIROLaser Advance on around 60 patients with primary teeth or not fully developed permanent teeth in our pediatric dental clinic (the treatment can also be done with SIROLaser Xtend). After exposing the pulp under local anesthesia, it was removed with a sterile bur; the following depuration and sterilization of the pulp area was performed with a laser with the preset parameters for pulpotomies (power output 3 W pulsed, duty cycle 50 %, frequency 5 Hz) using a laser fiber with a diameter of 200 mm in direct contact. Afterwards, the pulp was rinsed with chlorhexidine. The coagulation of the laser was sufficient, so the use of ferrous sulfate was not necessary. Care was taken for the bleeding to stop within a few minutes. Calcium hydroxide was applied to the rest of the pulp and the tooth was filled. A follow-up check took place after 7 days, 28 days and 6 months.

Desensitization

Treatment of the patients took place only in the dental practice of Jesko Gärtner and performed solely by him—the same applies to the stimulations before and after the treatments. The content of the treatment was the triggering of hypersensitivity through defects to the cervical region of the tooth and gingival recession of different etiology (Fig. 2). This triggered a sensation of pain via tactile or evaporative stimulations.

A total of 16 patients—10 females and 6 males—between the ages of 19 and 52 were treated. In these patients, 47 teeth were treated with the diode laser. Parallel to the treatment, the patients were asked to carry out regular and adequate oral hygiene at home. In preparation for laser irradiation, a professional dental cleaning was performed. In addition to the general oral health and oral hygiene status of the patients, the vitality of the affected teeth was determined and documented right before the investigation. The sensation of pain was reviewed and assessed by the patients in the following way:²³

Tactile stimulation

For the tactile stimulation, a WHO periodontal probe (Aesculap DB 767 R, Tuttlingen, Germany) was guided in a lat-

eral and vertical movement over the affected tooth surface (Fig. 3).

Cold air stimulation

After tactile stimulation, the respective tooth surfaces were blown with the air blower (maximum output) of the dental unit for 5 seconds. At the same time, the dentist covered the neighboring teeth with his fingers to avoid triggering any additional irritation; a rubber dam for isolating the area was purposely not used. All of the stimulations were performed on clean, air-dried surfaces and carried out by the same dentist. The stimulation was interrupted if there was a sensation of pain or after a maximum of 5 seconds.

The pain intensity was documented directly before and after the laser irradiation (initial value) using a numerical scale of 1 to 10 (Tab. 1). In a further control process carried out after 14 days, application of the fluid and irradiation with a diode laser was repeated and the pain sensation was documented.²⁴

Application of the fluoride was carried out 30 seconds before laser irradiation.

Numerical rating scale of pain intensity	Translation of verbal rating scale
0	No pain
1–3	Mild pain
4–6	Moderate pain
7–9	Severe pain
10	Intolerable pain

Tab. 1: Comparison of numerical and verbal assessment.

The patient group was arranged with the following exclusion criteria:^{13,25}

- Active periodontal illness
- Carious lesions on the affected teeth
- Tooth fractures
- Enamel cracks
- Regular intake of painkillers, tranquilizers or antidepressants
- Soft tissue management within the last six months.

Course of treatment

After the initial pain situation was documented, the exposed and pain-sensitive buccal tooth surfaces were coated with a fluoride-containing fluid and, after a wait time of 30 seconds, were treated with laser irradiation (970 nm, 500 mW, approx. 15 J/cm², cw) for 30 seconds. The irradiation was done in a non-contact procedure at a distance of 5 mm (Fig. 3). In total, each tooth was irradiated for 30 seconds at 3 intervals. Isolation of the neighboring teeth was done with cotton rolls. Following the last interval, the pain situation was diagnosed again and repeated in another inspection of this procedure after 14 days and 28 days. The entire treatment period was from July 2009 to April 2013; the longest inspection interval is 29 months.

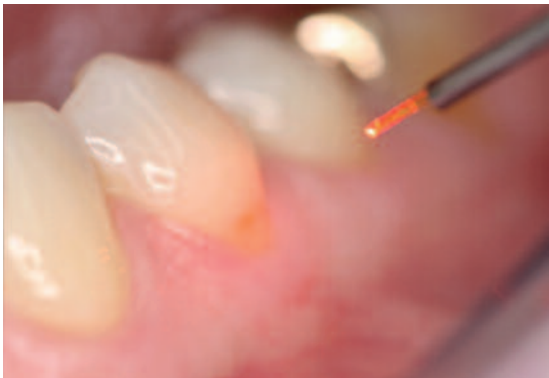


Fig. 4: Irradiation of the tooth surface with SIROLaser Advance.

Parallel to laser irradiation, all the patients received individual oral hygiene instructions as well as specially selected toothbrushes (Curaprox 820 supersoft, Curaden, Kriens, Switzerland). After the last check-up, it was suggested that the patients use a soft toothbrush for the continuing oral hygiene at home (Curaprox 820 soft, Curaden, Kriens, Switzerland) and a toothpaste containing potassium nitrate (Sensivital, Sunstar, Etoy, Switzerland).

Results

Pulpotomy

In the follow-up period, the pulpotomy was clinically successful in approximately 95 % of the patients, i.e., the tooth was free of symptoms and further surgery was not required.

Desensitization

Almost all of the patients reported a very significant improvement in their dentin hypersensitivity within the treatment period of one month. On average, the premolars and canines were most often irradiated (34 % and 32 %, respectively) in the supervised patient group. An average of 2.94 teeth was irradiated per patient. The age range of the patients was between 19 and 52. The results show differences for the pure application of desensitizers with regard to tactile as well as air stimulation—related to this, a considerably stronger therapeutic effect results than exhibited with nitrate and fluoride used as the sole application. After application of the fluoride fluid and irradiation with the diode laser, 63 % of the teeth were at pain level 0 and 27 % at level 1–2, thus the absolute reduction of dentin hypersensitivity is 91 % and in 9 % there were variable results (moderate sensation of pain: 6 %; severe sensation of pain: 2 %).

The longest monitoring period is 29 months. In these cases, there is still an improvement with a pain level of between 0 and 2.

Discussion

Pulpotomy

The results of the pulpotomy performed with a diode laser (95 % success rate) are close to the values given in the liter-

ature for the Er:YAG laser (75 %) and Er,Cr:YSGG (80 %) by Olivi et al.²⁶ Gutknecht gives a success rate of 99 %.²⁷ For the Nd:YAG, Liu gives a clinical success rate of 97 %.¹⁰

Desensitization

Dentin hypersensitivity is characterized by the fact that all stimulations—which are usually not problematic on healthy tooth surfaces—trigger a sensation of pain and consequently limits oral hygiene. Due to this drawback, there is an accumulation of plaque, which also promotes periodontal deterioration and leads to a vicious cycle. Overall, dentin hypersensitivity represents a widespread problem, which requires effective treatment. In this regard, laser—also in combination with fluoride—may be an appropriate treatment. Laser light irradiation encompasses all the important criteria for successful treatment of dentin hypersensitivity: It affects cellular metabolism, triggers anti-inflammatory mechanisms and relieves pain. These effects allow an explanatory approach that leads to high effectiveness.²⁴ In addition, it is painless, quick, easy to use, minimally invasive (conservative) and the patient acceptance rate is excellent. Due to the multifactorial occurrence of dentin hypersensitivity, other factors like habit or occlusal components should not be disregarded. Overall, comprehensive treatment concepts will be necessary for successful treatment of these patient groups.¹³ The results already demonstrate the high effectiveness of laser irradiation—also compared to the application of desensitizers.²¹ In order to make an actual statement on the lasting value of these results, long-term studies are certainly necessary. In these studies, the sustainability of the results of laser irradiation needs to be examined. The benefits for the patient and the therapeutic long-term effects need to be elaborated.

In this regard, further efforts should be taken to better understand the biochemical and physiological processes as well as the formation mechanisms.

Conclusion

The results show the high effectiveness of laser treatment and the very fast reduction of pain at the same time. This corresponds to the existing research, which currently describes the best results in the area of laser irradiation with simultaneous application of a topical fluid.^{16,17,18} Generally, the results show that the response situation of the tissue structures seems to decrease with age and the tissue response to therapeutic measures diminishes between the ages of 40 and 45; at the same time, the effects of irradiation are not as strong and first occurred after the second or third irradiation session.^{16,17,18}

In terms of the outlook for possible long-term studies, it is noted that the longest control period in the patient group investigated is 29 months and these patients also continue to present themselves as pain free or at a pain level of 1 to 2, thus the long-term effects of the treatment performed can evidently be established. ◀

Literature

1. Miron MI, Dodenciu D, Lungeanu D, Balabuc CA, Filip LM, Todea C. An Evaluation of the 980 nm GaAlAs High-Level Diode Laser in the Treatment of Dentine Hypersensitivity. *TMJ*. 2007;4:280–286.
2. Walters P. Dentinal Hypersensitivity: A Review. *The Journal of Contemporary Dental Practice*. 2005;2:107–117.
3. Endodontie im Milchgebiss. Wissenschaftliche Stellungnahme der Deutschen Gesellschaft für Zahn-, Mund- und Kieferheilkunde. 2002.
4. Hubertus van Waes, Paul W. Stöckli. *Farbatlanten der Zahnmedizin*. Vol. 17. *Kinderzahnmedizin*. Stuttgart:Thieme;2000:223ff.
5. American Academy of Pediatric Dentistry. Guideline on pulp therapy for primary and immature permanent teeth. Chicago (IL). American Academy of Pediatric Dentistry (AAPD). 2009.
6. Zarzar PA et al. Formocresol mutagenicity following primary tooth pulp therapy: an in-vivo study. *J Dent*. 2003;3:479–485.
7. Dean JA et al. Comparison of electrosurgical and formocresol pulpotomy procedures in children. *Int J. Paediatr Dent*. 2002;12:177–182.
8. Smith NL et al. Ferric sulfate pulpotomy in primary molars: a retrospective study. *Pediatr Dent*. 2000;22(3):192–199.
9. Shoji S, Nakamura M, Horiuchi H. Histopathological changes in dental pulps irradiated by CO₂ laser: a preliminary report on laser pulpotomy. *J Endod*. 1985 Sep;11(9):379–384.
10. Liu JF. Effects of Nd:YAG laser pulpotomy on human primary molars. *J Endod*. 2006 May;32(5):404–407.
11. Kotlow L. Lasers and pediatric dental care. *Gen Dent*. 2008 Nov–Dec;56(7):618–27.
12. Saltzman B, Sigal M, Clokie C, Rukavina J, Titley K, Kulkarni GV. Assessment of a novel alternative to conventional formocresol-zinc oxide eugenol pulpotomy for the treatment of pulpally involved human primary teeth: diode laser-mineral trioxide aggregate pulpotomy. *Int J Paediatr Dent*. 2005 Nov;15(6):437–447.
13. Umberto R, Russo C, Palaia G, Tenore G, Del Vecchio A. Treatment of Dentine Hypersensitivity by Diode Laser: A Clinical Study. *International Journal of Dentistry*. 2012.
14. Gilliam DG, Orchardson R. Advances in the treatment of root dentine sensitivity: mechanisms and treatment principles. *Endodontic Topics*. 2006;13:13–33.
15. Asnaahari M, Moeini M. Effectiveness of Lasers in the Treatment of Dentine Hypersensitivity. *Journal of Lasers in Medical Sciences*. 2013;4(1):1–7.
16. Botzenhart U, Braun A, Frentzen M. Laser treatment of dentine hypersensitivity. Part I. *Laser*. 2012;1:20–25.
17. Botzenhart U, Braun A, Frentzen M. Laser treatment of dentine hypersensitivity. Part II. *Laser*. 2012;2:24–27.
18. Botzenhart U, Braun A, Frentzen M. Laser treatment of dentine hypersensitivity. Part III. *Laser*. 2012;3:12–15.
19. Blaggana A, Vohra P, Nagpal A. Diagnosis and Treatment of Dentinal Hypersensitivity. *Journal of Innovative Dentistry*. 2001;3.
20. Sicilia A, Cuesta-Frechoso S, Angulo J, Pordomingo A, De Juan P. Immediate efficacy of diode laser application in the treatment of dentine hypersensitivity in periodontal maintenance patients: a randomized clinical trial. *Journal of Clinical Periodontology*. 2009;36:650–660.
21. Ladalardo T, Pinheiro A, de Carvalho Campos RA, Brugnera Junior A, Zanin F, Albermaz PL, Weckx L. Laser therapy in the treatment of dentine hypersensitivity. 2006.
22. Benetti AR, Franco EB, Franco EJ, Pereira JC. Laser Therapy for Dentine Hypersensitivity: A Critical Appraisal. *Journal of Oral Laser Applications*. 2004;4:271–278.
23. Akca AE, Gökce S, Kürkcü M, Özdemir A. A Clinical Investigation of Low Level Laser Irradiation on Hypersensitivity Dentine. *Cilt*. 2006; 2:94–99.
24. Yui K, Goncalves S, Di Nicolo R. Low level laser therapy for dentine hypersensitivity. *Cienc Odontol Bras*. 2003;6:17–24.
25. Marsilio AL, Rodrigues JR, Bühler Borger A. Effect of the Clinical Application of the GaAlAs Laser in the Treatment of Dentine Hypersensitivity. *Journal of Clinical Laser Medicine and Surgery*. 2003; 5:291–296.
26. Olivi G, Genovese MD, Maturo P, Docimo R. Pulp capping: advantages of using laser technology. *Eur J Paediatr Dent*. 2007 Jun;8(2):89–95.
27. Gutknecht N et al., Lasers in Pediatric Dentistry – A Review. *J Oral Laser Applications*. 2005;5:207–218.